

Study on myopathy, neuropathy in STZ-induced Diabetes mellitus experimental rats Rattus norvegicus and the role of arginine in prevention of complications

Mohammed k. Hassani and Maha K. Ibrahim

Dept. of Science ,College of Basic Education ,Missan University

Dept. of Biology ,College of Science ,Basrah University

Abstract

The study was designed to clarified the effect of induced diabetes mellitus (DM) on myopathy , neuropathy in addition to the possible role of arginine in prevention of (DM) complications at each period (15,30,45) days post induction .

Findings on non-sectioning method (silver nitrate) impregnation indicated that the isolated muscle fibers from skeletal muscle (Biceps - Triceps-Gastrocnemius) showed mild degeneration, increased myonuclei , areas of necrosis , reduced axons diameter, the motor-end plates endings retracted , undifferentiated nuclei at sole plate with dense sarcolemma at the neuromuscular junction , through the (30) days the changes more severity , results indicated to muscle fibers degeneration , most vesicular myonuclei appeared pyknotic , demyelination nerve fibers , atrophied axons , remnants of nerve fibers , tortous and the sarcolemma showed discontinuity , whereas isolated muscle fibers from diabetes muscles at (45) days revealed to sever reduction in muscle fiber diameter , some with cross striations , others have no Z-line , segmental demyelination , the motor endings lost their connection with their original nerve fibers and ends with retracted nerve endings compared to isolated muscle fibers from skeletal muscles impregnated with silver nitrate related to diabetes rats treated with arginine clarified that more regular muscle fibers , supplied with myelinated fibers , new formation of motor - end plate , the muscle fibers with cross striations , new myotubes , primary and secondary terminal branches end with developed nerve endings , these endings have variable shape, like

cone , twigs , configurations at (15, 30) days post treated , the isolated muscle fibers from rats treated with arginine at (45) days post treated showed more myelinated fibers with constrictions , and variable endings , simple , secondary and grape like .

Introduction

Diabetes is one the major diseases with various complications. The prevalence rate is 8.9%-12.3% in human population , it leads to various complications in long term, neuropathy is one of the most common diabetic complications of the symmetrical diabetic neuropathies, distal symmetrical polyneuropathy, a predominantly axonal, length dependent neuropathy is most prevalent (Zangiabadi *et al.*, 2007 ; Zangiabadi *et al.*, 2011) .

Hyperglycemia in diabetic patients as the main factor of diabetic neuropathy induces oxidative stress through various cellular pathways such as increasing aldose reductase activity , increasing glycation end-products and altering protein kinase C activity. Longstanding hyperglycemia through producing a large amount of Reactive Oxygen Species (ROS) can damage mitochondrial DNA in dorsal root ganglia leading to peripheral nerves dysfunction (Schmeichel *et al.*, 2003; Srivastava *et al.*, 2005; Sugimoto *et al.*, 2008 ; Yamagishi *et al.*, 2008).

Several studies have proposed that oxidative stress is one of the major factors impairing sensory nerves and dorsal root ganglia (Sharma *et al.*, 2009).

A number of mechanisms have been proposed to link chronic hyperglycemia to diabetes-induced deficits in motor and sensory nerve conduction velocities (MNCV and SNCV) and small fibers sensory neuropathy, the vascular concept of PDN implies that diabetes-induced endothelial dysfunction with resulting decrease in nerve blood flow (NBF), vascular reactivity, and endoneurial hypoxia has a key role in

functional and morphological changes in the diabetic nerve (Cameron *et al.*, 2001). Evidences suggest that oxidative stress and free radicals play an important role in the pathogenesis of diabetes mellitus and diabetic complications including tissue damage and injury (Zangiabadi *et al.*, 2011). Vascular defect and resistance following oxidative stress decreases blood flow and causes hypoxia and decrease of nerve function leading eventually to Nerve Conduction Velocity (NCV) reduction (Saini *et al.*, 2007) .



Diabetes mellitus is characterized by peripheral neuropathy of sensory and motor nerves, Peripheral neuropathy syndrome was initially diagnosed clinically by the appearance of pelvifemoral muscle weakness and muscle wasting. Similarly, variations were reported in the intramuscular nerves after a biopsy study of diabetic subjects. These peripheral nerves and muscles dysfunctions have been demonstrated in both humans and rodents (Woolf & Manlis, 1957 ; Mayer & Tomlinson, 1983 ; Picard & De La Monte,1987 ; Harati, 1987).

Diabetes is associated with reduced plasma concentrations of arginine, and L-arginine supplementation normalized the endothelium-dependent relaxation in diabetic aorta by enhancing NO availability and restoring the acetylcholine-stimulated (cGMP) generation (Barbosa *et al.*,2013).

Abnormal endothelial function is a salient feature of vascular disease in diabetes that characterized by a decrease in nitric oxide (NO) synthesis or bioavailability, NO is produced by endothelial NO synthase (eNOS) through the oxidation of its substrate L-arginine , So release of NO plays a critical role in preserving vascular homeostasis by inhibiting vascular tone, platelet aggregation, leukocyte recruitment and infiltration into the vessel wall, and smooth muscle cell proliferation and migration (Loscalzo & Welch, 1995 ; Forstermann & Sessa, 2012).

Materials and methods

Experimental animals

Thirty healthy adult females Wistar albino rats (*Rattus norvegicus*) age (10-12) weeks and the average weight (225 ± 25) gm, which are breed at the animal house of the Science college , Al-Basarah University, the animals are housed under controlled standard conditions in a temperature (20-23) ° C , controlled room on a (12: 12) Light: Dark cycle, they are randomly isolated in plastic cages with hygienic bed and were fed on standard laboratory food, the animals divided into two group (non diabetic and diabetic group) with about (24) female in diabetic group and (6) female nondiabetic group (control group) , The diabetic group are subdivided into two groups (12) of each one, both of them are single injected intraperitoneally with streptozotocin (STZ) (60 mg/ kg of body weight), with mean (10) rats females for each period (15, 30, and 45) days post induction of DM. the first subdivided group(diabetic group) were given tap water but the second subdivided group (diabetic treated with arginine) were given tap

water containing L-arginine nitro-L-arginine methyl ester dissolved in the drinking water at 10 mg/L, 3 days after (STZ) injection (Ki chul choi *et al.*, 1999).

Sacrificed the experimental rats

Fasting overnight experimental rats from each group (treated and control) were randomly sacrificed after being anaesthetized with overdose of chloroform and Sacrificed on (15 - 30 - 45) day post diabetic induction, then samples were collected included skeletal muscles from fore and hind limbs (Triceps , Biceps , gastrocnemius). All skeletal muscles that have been isolated from fore and hind limbs related to control and treated groups were immersed in Decastro fixative (specific for this experiment) afreshly prepared solution , according to (Barker & Ip, 1963 ; Al-malak ,1992).

Results

Findings from light microscopic examination indicated that all the muscle fibers related to Triceps brachii, Biceps brachii and Gastrocnemius muscles from control rats appeared as cylindrical structures tubes with tapers endings , clear cross striations with **Z**-line , vesicular , peripherally nuclei , each muscle fiber surrounded with dense sarcolemma showed as a thin wavy band darker than the muscle fibre (fig 1), fore and hind limbs muscles supplied with the intramuscular nerve trunk form plexus extend in the muscle connective tissue as myelinated and non-myelinated nerve fibers which subdivided to end freely in the muscles , variable points of nerve entry to the muscles either to the muscle belly or near the fibers endings, traced and branched to pre-terminal axons and terminals axons that are derived from a single pre-terminal or from terminal node (fig 2,3)

Variable nerve endings within control skeletal muscles like motor - end plates that the axons branched to fine tapers endings with sole - plate , clear dense nuclei while other terminal axons subdivided to two branches and this formed secondary branches to end as secondary endings , the nervous arborization of the end-plates easily stained , the root is dark stained , the branches are thin , visible, club -like, swelling and containing dense granules, other endings appeared as large end plate without terminal enlargement, and irregular trial ending showed at the polar end of muscle fiber (fig 4,5).

Recent study clarified the morphological and structural changes on isolated muscle fibers with their nerve fibers and terminals nerve endings from diabetes rats

after(15,30,45)days post diabetes induction, results at (15) days showed mild degeneration, area of necrosis, increased with myonuclei under the sarcolemma which appeared folded and irregular , mild inflammatory cells distributed irregularly while some of muscle fibers appeared normal with cross striation and peripheria nuclei , some nerve fibers still myelinated , sometimes the axon extend between muscle fibers , showed mild degeneration with accumulation of dense granules (fig 6,7), in addition each muscle fibers supplied with dense thick nerve fibers showed like stumps or thick myelinated fillaments divided into two bifurcate and terminate as free nerve endings, and motor- end plates within the muscle fibers or may be the terminal end as conical ending (fig 8 ,9), at this period of diabetic the motor-end plates noticed retracted, degenerated, not well developed and with undifferentiated nuclei at the sole plate , other terminal branches showed hypertrophied , more darker and formed sprouts within the muscle fibers or extend between muscle fibers and others endings like grape, the sarcolemma at the neuromuscular junction appeared dense and folded (fig 10,11,12,13) .

At (30) days post diabetes induced the muscles prepared with silver nitrate impregnation showed more alterations with muscle fibers the nerve fibers and nerve endings , partial degeneration of muscle fibers, the striation less obvious , vesicular myonuclei and inflammatory cells , the nerve fibers extend from nerve trunk ,these nerve fibers appeared demyelination, tortous , variable furcation , atrophied axons, remnants of nerve fibers, hypertrophied terminals with dense secretory granules ,or non - well developed motor - end plates and sometimes extend like irregular endings along the muscle fiber surface (fig 14,15,16,17,18,19).

After (45)days of diabetes induction in rats , most of muscle fibers isolated from the skeletal muscles was degenerated , inflammatory cells infiltrated and heamorrhage between muscle fibers , the sarcolemma was thick and interrupted along the muscle fiber surface , the cross striation not clear and others have no **Z** - line , the changes extend to the muscle fibers endings which appeared degenerated with thickening sarcolemma, the nerve fibers branched from nerve trunk as myelinated and segmental demyelination, most of these fibers lost their myelin sheath , irregular , show degenerated zones , pyknotic nuclei of schwann cells and extensive ramification of fine nerve fibers many of which end in knobs or rings , also abnormal motor terminals showed as fine nerve sprouts arise from terminal arborization and spread in all directions, in addition degeneration of most equatorial region myonuclei of muscle spindle and the capsule that surrounded this region,

degenerated, retracted motor- end plates , changes with secretory granules and thick folded of both sarcolemma and neurolemma , the main nerve fibre branched to two primary branches and sometimes the primary also subdivided into fine secondary branches ending with un developed motor endings, the nerve endings also in diabetes muscles showed like bunch of grapes ,contracted structure or shrinkage endings , sometimes the terminal branched regular but they don't end in a swelling , some motor-end plates lost their connection with the origin nerve fibers (fig 20,21,22,23,24,25,26,27,28).

The study clarified the role of arginine on diabetes skeletal muscle at each period (15,30,45) day post diabetes induction and results showed some normal muscle fibers resemble the control muscle fibres , obvious cross striation , more regular longitudinal myonuclei with normal blood vessels, other muscle fibers appeared with regular sarcolemma and Z- line and new myotubes formation with central nuclei arrangement can be noticed at (15) days . Many nerve fibers supplied the isolated muscle fibers from Gastrocnemius muscle at this period, showed well neuromuscular junction , that the myelinated fiber showed segmental myelination and extend along the muscle fiber surface with new formation of motor - end plate , more than end – plate at the same muscle fibre , more than terminal branches from one axon with primary and secondary nerve endings distributed at different regions of muscle fibers , in addition to the return of normal myelination to some nerve fibers (29,30,31,32,33).

Variable features were recorded in isolated muscle fibers from fore and hind limbs skeletal muscles related to diabetes rats and treated with arginine at (30) days post diabetes induced there was normal muscle fibers although others fibers showed degeneration with infiltration of inflammatory cells and nerve fibers remnants , new myotubes , normal appearance of muscle spindles with well developed equatorial region and polar regions , myelinated nerve fibers subdivided to branches either primary or secondary terminal branches and terminate with developed nerve endings , some of these endings motor-end-plates , configuration endings , cone like shape , twigs around muscle fibers and hypertrophied well developed motor endings (fig 34,35,36,37,38,39).

The recent study clarified the changes of muscle fibers and their nerve fibers supplies, type of endings at (45) day post diabetes induced and treated with arginine , isolated muscle fibers appeared normal , most of with striations ,

peripherall vesicular myonuclei , regenerated myotubes and all the myelinated nerve fibers showed constrictions along their length , myelinated fibers subdivided to preterminal branches , its width regular , along its length there was interrupted and dark granulation and different types of developed endings distributed regularly within and between muscle fibers some like coiled , vesicular endings , simple and secondary endings, configuration nerve endings and grape-like motor ending (fig 40,41,42,43).

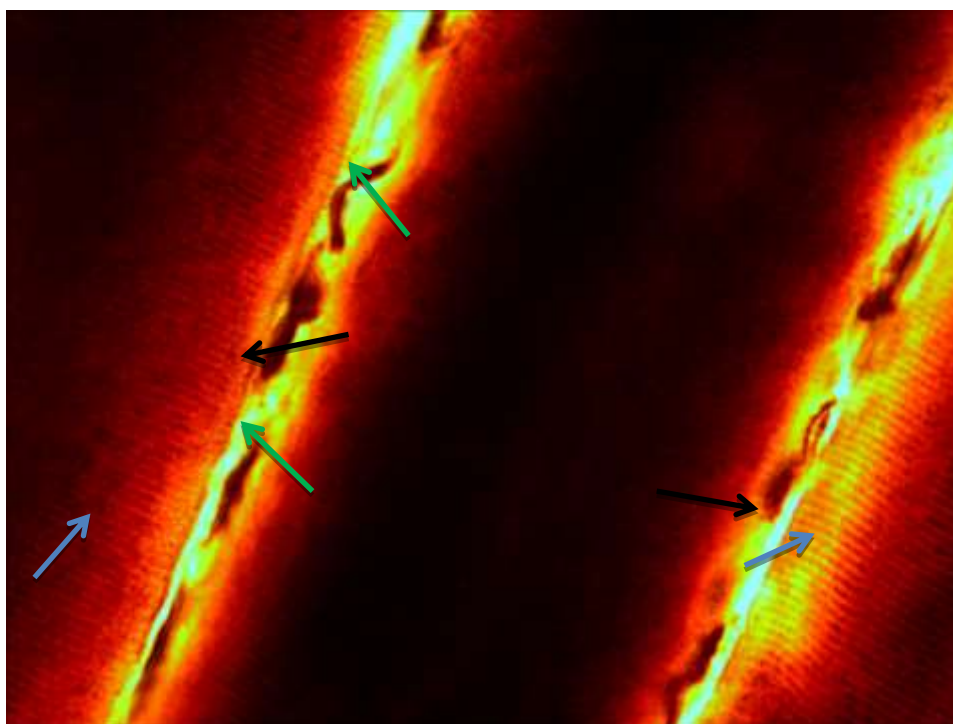





Fig (1) photograph on isolated muscle fibers from control gastrocnemius showed cross striation () of muscle fibers , peripherally vesicular myonuclei () , normal sarcolemma () (silver nitrate stain 40X)

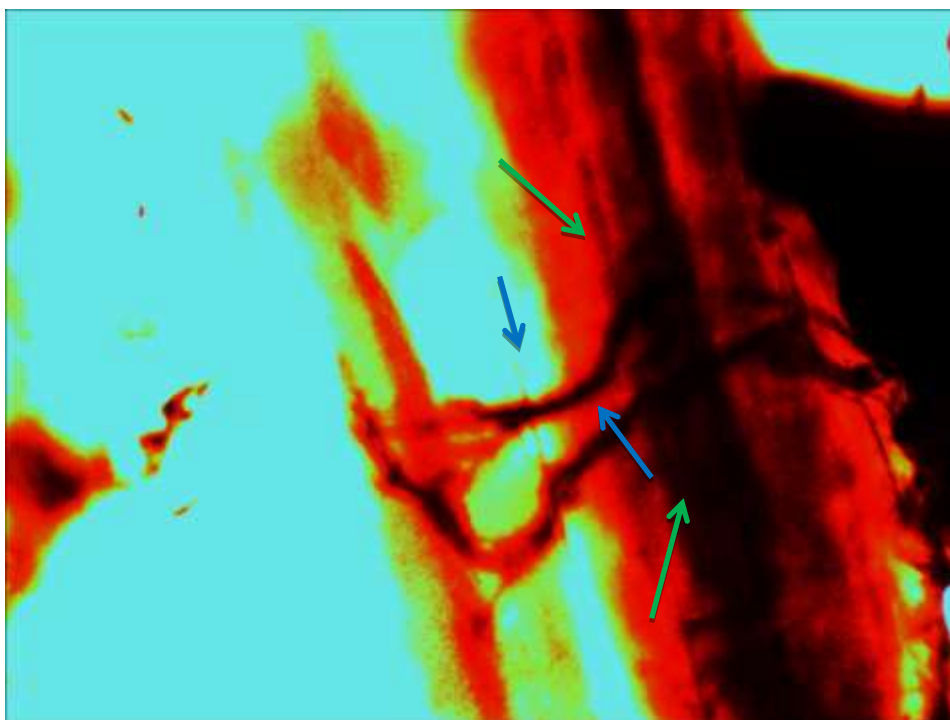




Fig (2) photograph on isolated muscle fibers from control gastrocnemius showed the myelinated nerve fibers () innervate normal muscle fiber () (silver nitrate stain 40X)

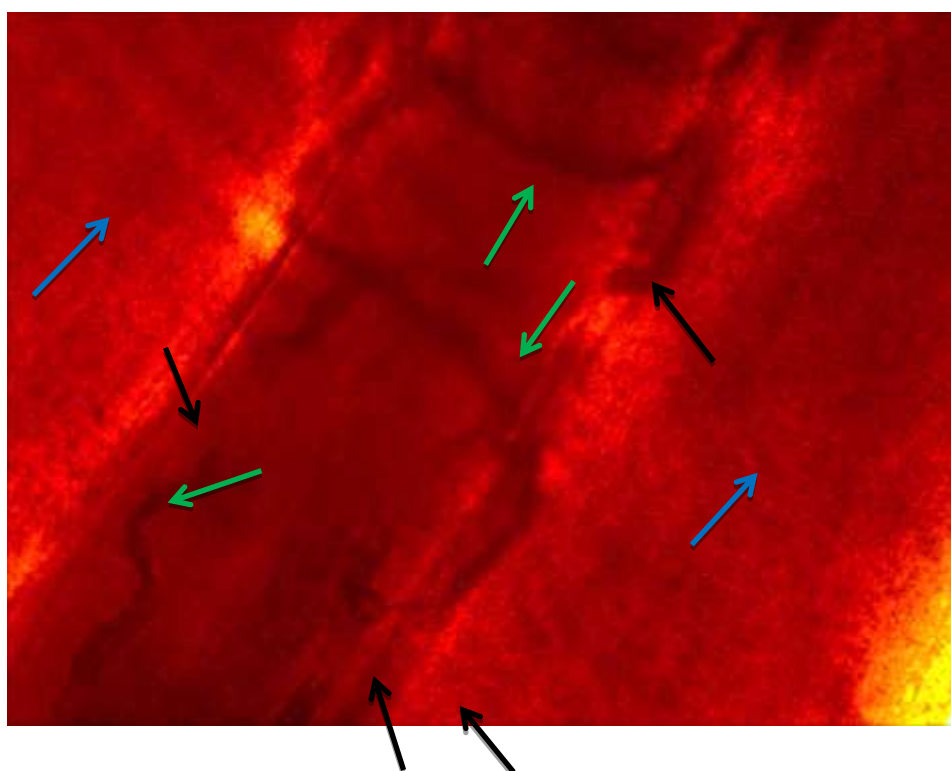





Fig (3) photograph on isolated muscle fibers from control Biceps showed cylindrical fibers (), innervated with branched myelinated fibers (), motor endings () (silver nitrate 40X)



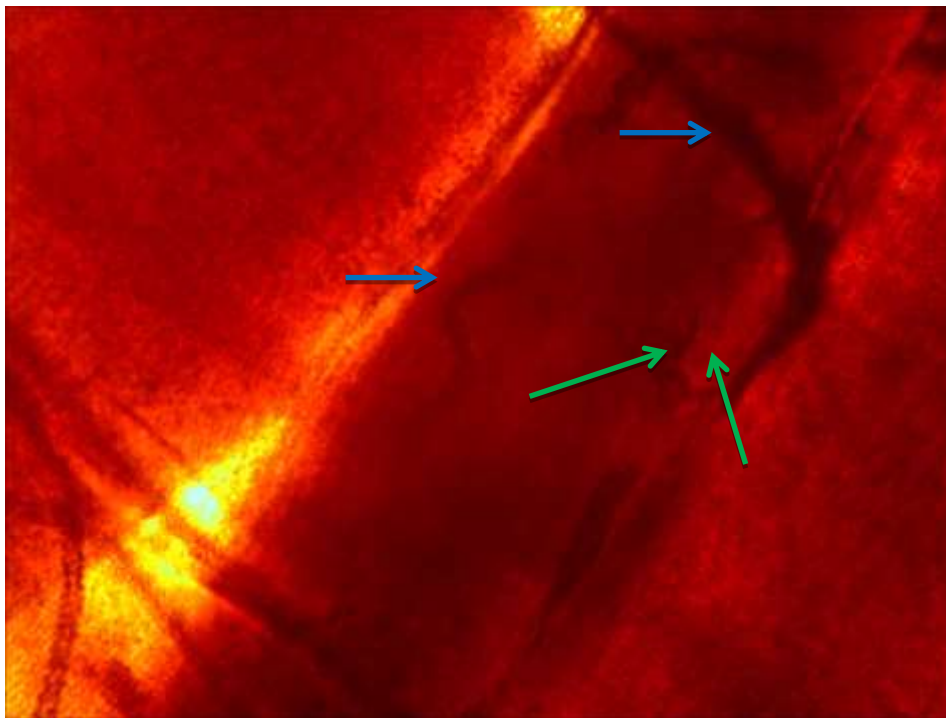


Fig (4) photograph on isolated muscle fibers from control Biceps showed more than one myelinated fibers () club-like ending () silver nitrate stain 40X)

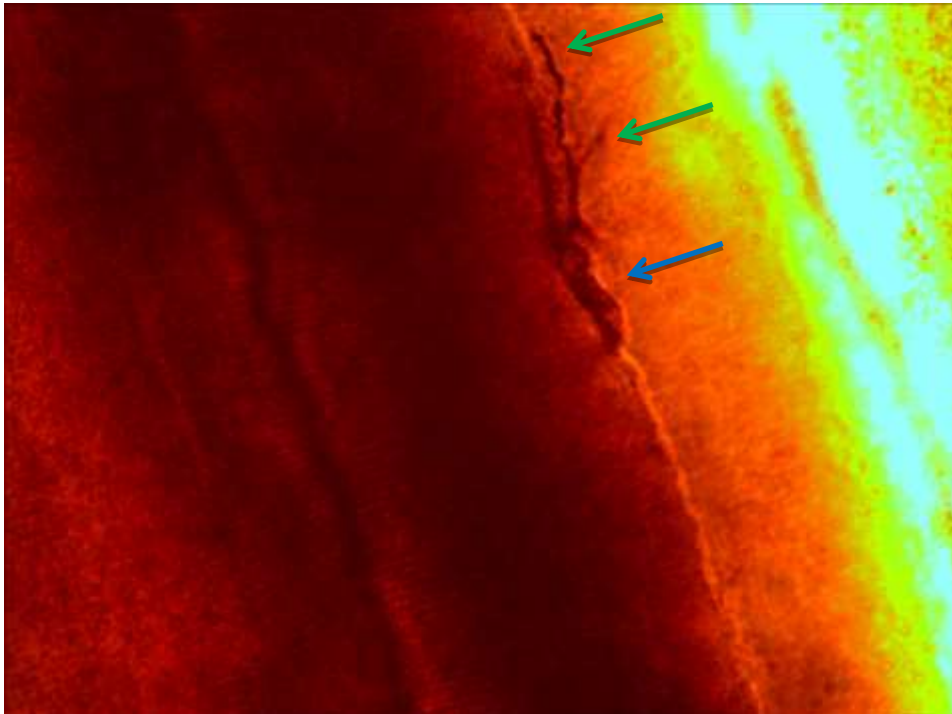





Fig (5) photograph on isolated muscle fibers from control Triceps showed broad-large end-plate

 () other ending ) without terminal branch (silver nitrate stain 40X).



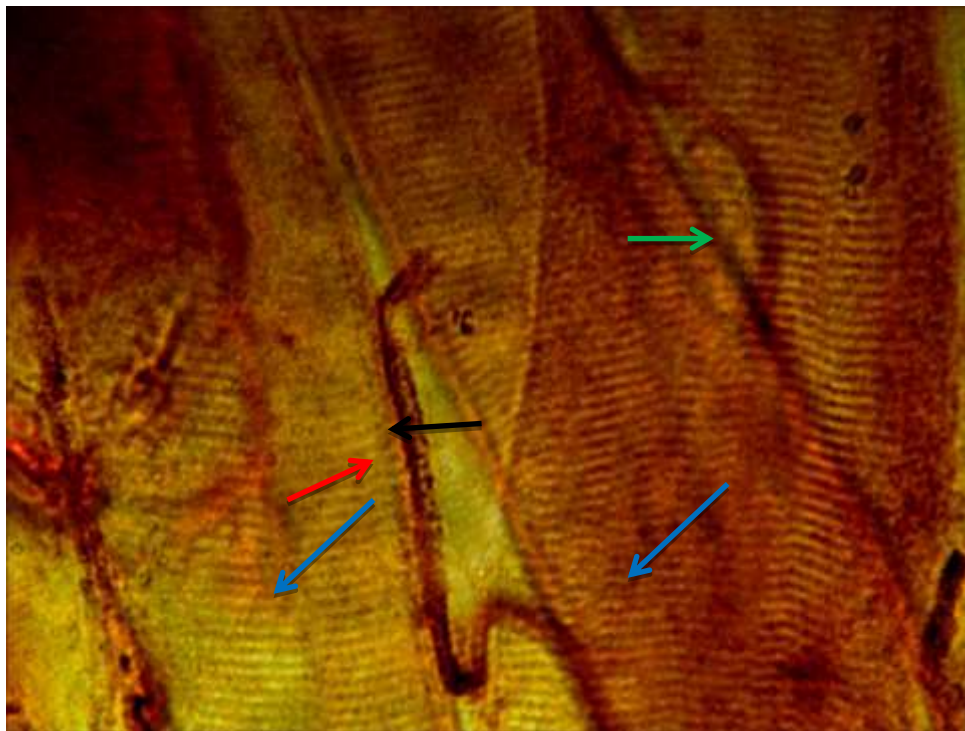






Fig (6) photograph on Biceps muscle fibers after (15) day of diabetes induction showed isolated muscle fibers with clear striation (), variable axons (), axon with mild degeneration (), dense granules accumulated () (silver nitrate stain 40X)

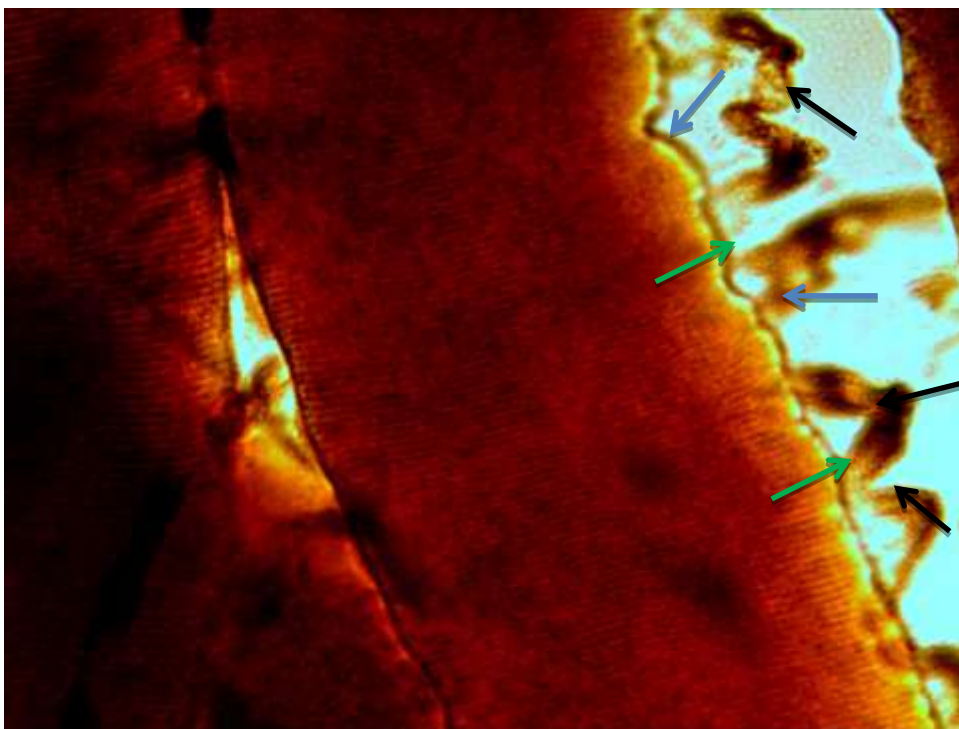





Fig (7) photograph on Gastrocnemius muscle fibers after (15) day of diabetes induction showed folded sarcolemma (), detachment () from muscle fiber surface , demyelination nerve fibers () silver nitrate stain 40X)




Fig (8) photograph on Gastrocnemius muscle fibers after (15) day of diabetes induction showed isolated muscle fibers (←→),crowded myonuclei (←→) (silver nitrate stain 10X)

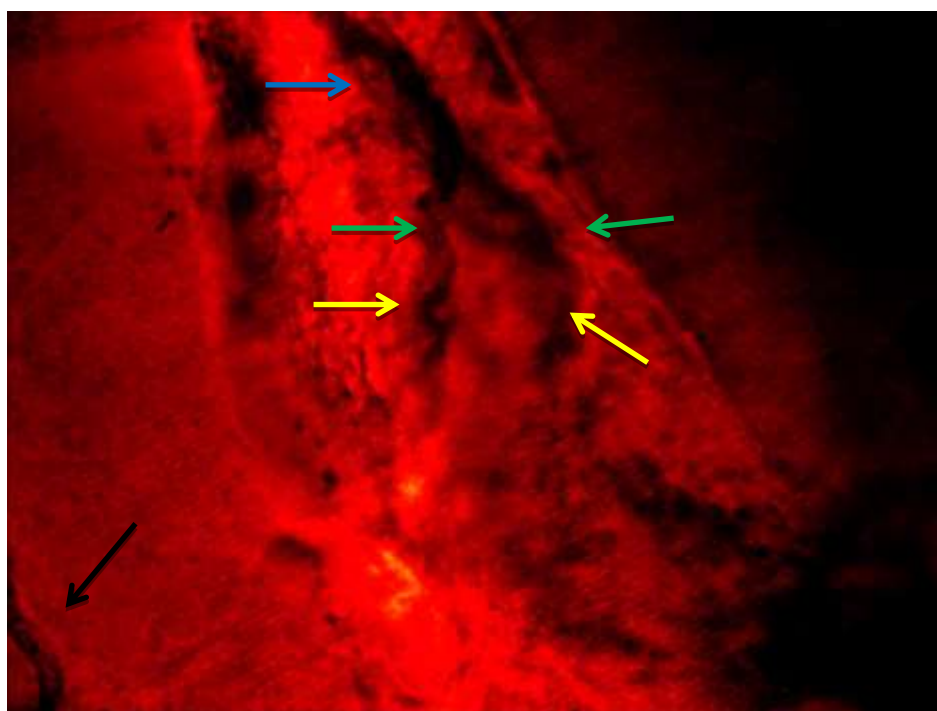


Fig (9) photograph on Biceps muscle fibers after (15) day of diabetes induction showed thick nerve fibers (←→), bifurcate into two terminal (←→) endings as free endings (←→),other end plate (←→) obvious (silver nitrate stain 40X)



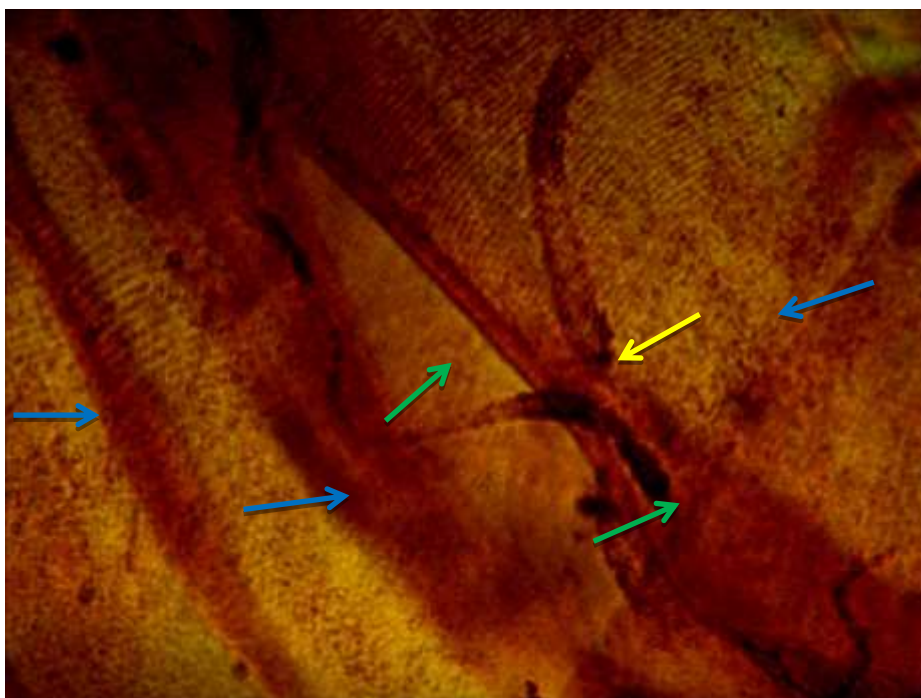





Fig (10) photograph on Biceps muscle fibers after (15) day of diabetes induction showed degenerated muscle fibers (), retracted nerve fibers () with demyelination, conical motor endplate ending () (silver nitrate stain 40X)

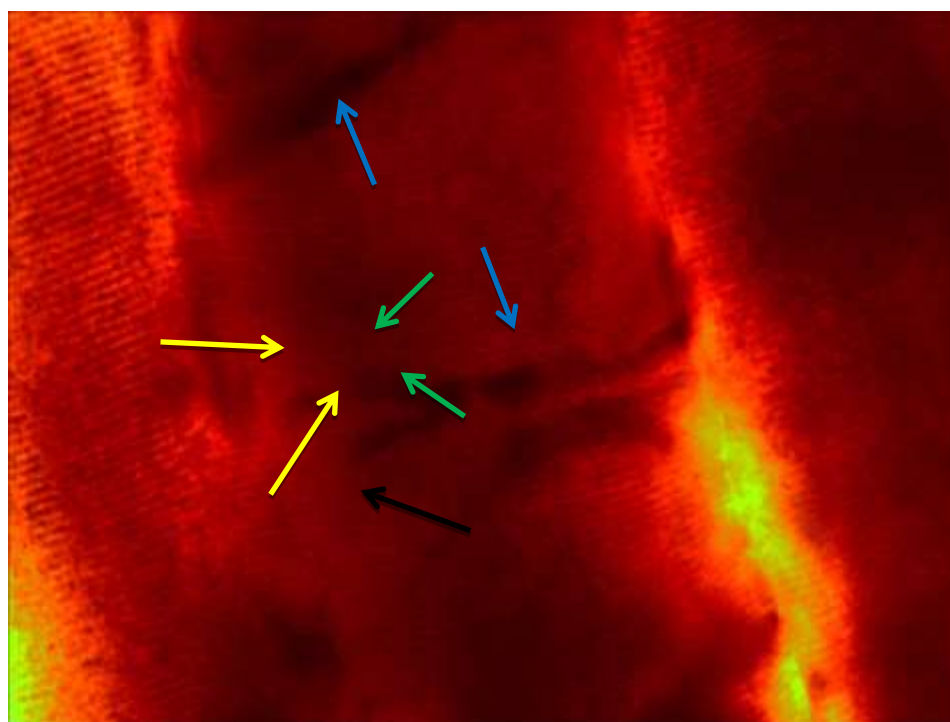






Fig (11) photograph on Gastrocnemius muscle fibers after (15) day of diabetes induction showed more than one sensory axons (), one bifurcate into two (), branches, innervate the muscle fibers (), each branch ends with motor end plate () silver nitrate 40X



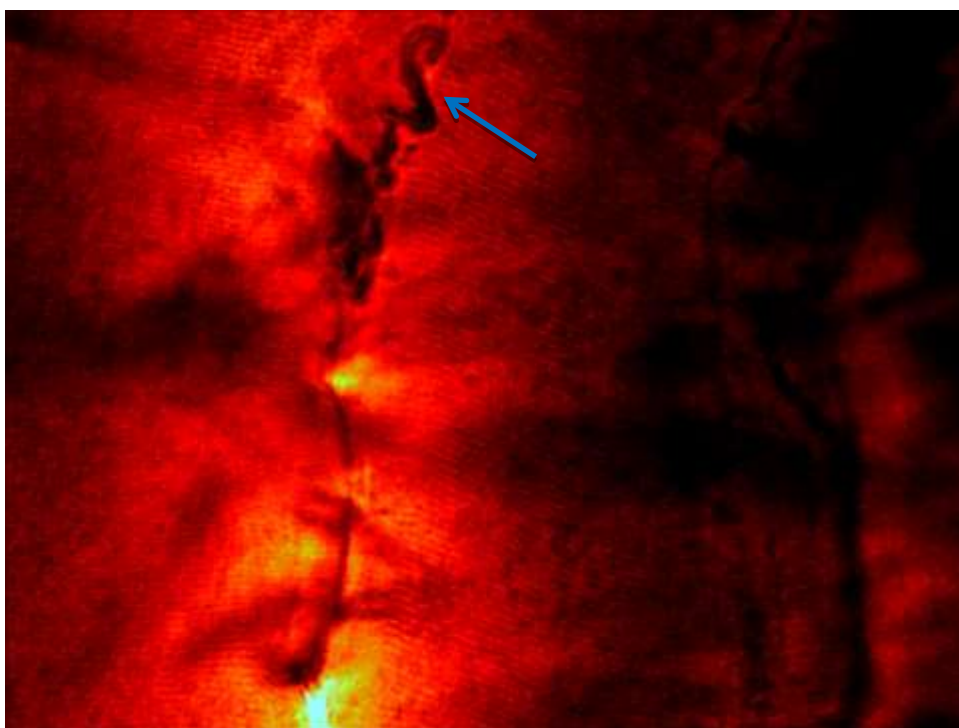



Fig (12) photograph on Gastrocnemius muscle fibers after (15) day of diabetes induction showed thick nerve fiber() , tortous , ending was appeared as grap-like ending (silver nitrate stain 40X)

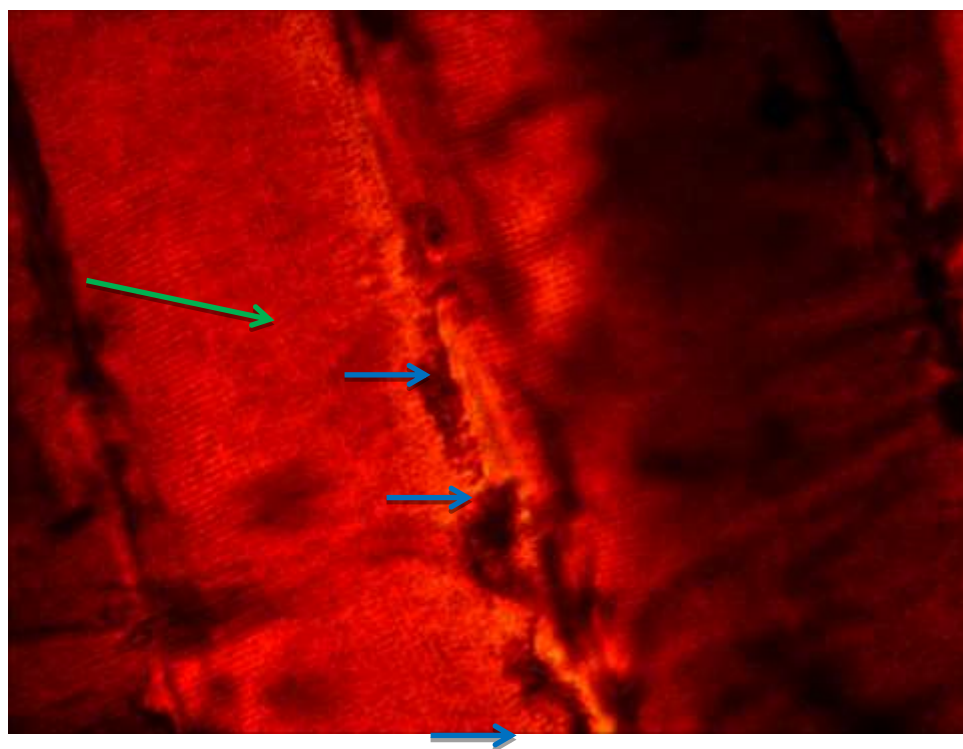




Fig (13) photograph on Gastrocnemius muscle fibers after (15) day of diabetes induction showed not - well developed motor end plate () within muscle fiber() (silver nitrate stain 40X)

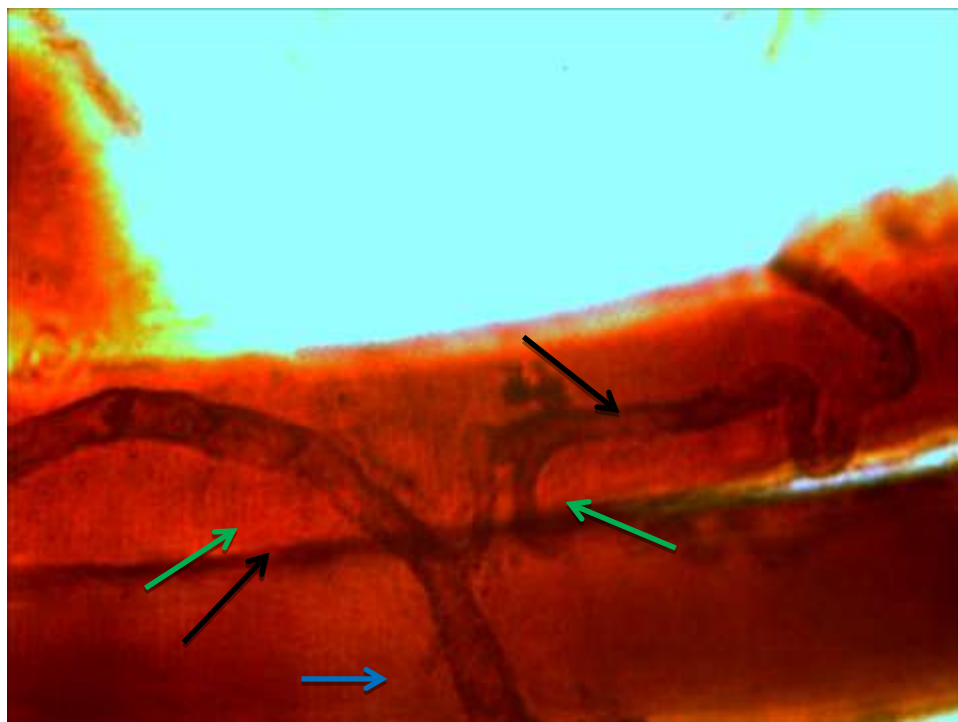


Fig (14) Isolated muscle fibers from Biceps at (30) day of diabetes induction showed demyelination of thick nerve fibers (→), bifurcate (→) into two branches , degenerated muscle fibers (→) (silver nitrate stain 40X)

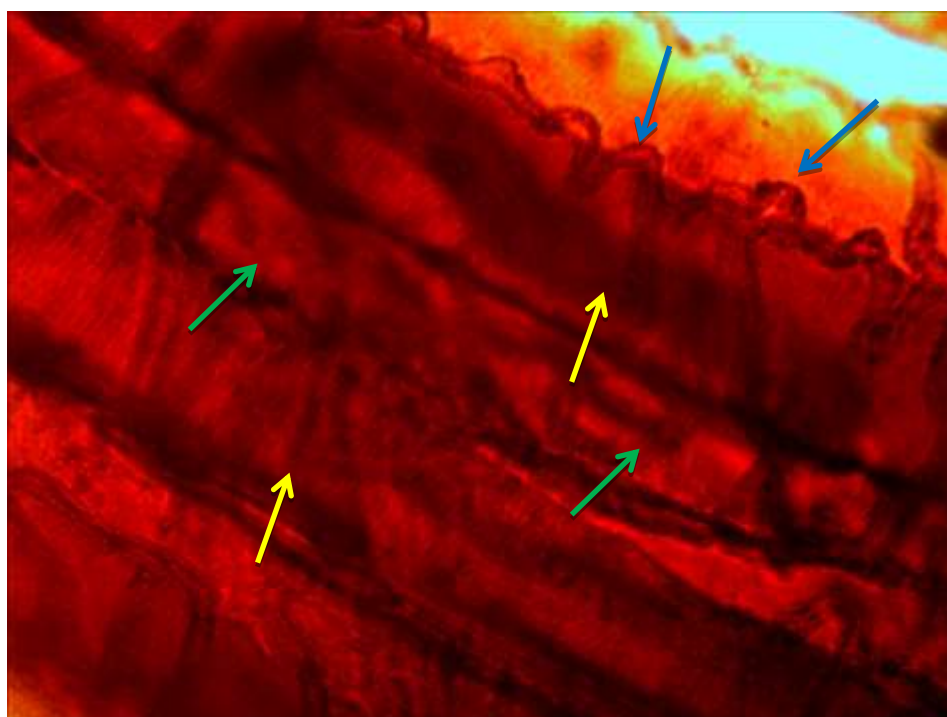


Fig (15) Isolated muscle fibers from Biceps at (30) day of diabetes induction showed folded nerve fibers (→), dense granules (→) associated with demyelination, thick sarcolemma (→) (silver nitrate stain 40X)

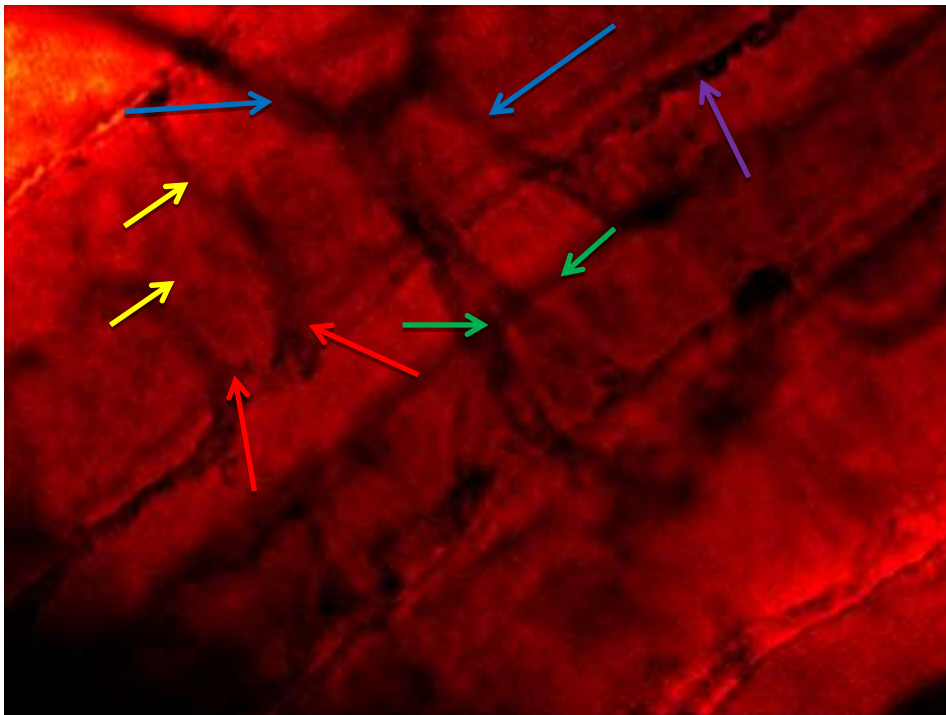








Fig (16) Isolated muscle fibers from Biceps at (30) day of diabetes induction showed atrophied nerve fibers (), some bifurcate to primary branches (), other lost their myelin () ends  with dense motor ending () and irregular , trial ending () also obvious (silver nitrate stain 40X).









Fig (17) Isolated muscle fibers from Triceps at (30) day of diabetes induction showed muscle fibers (), separated from each other by intercellular space () atrophied myonuclei (), demyelinated nerve fiber () with degeneration and inflammatory cells () noticed (silver nitrate stain 40X) .



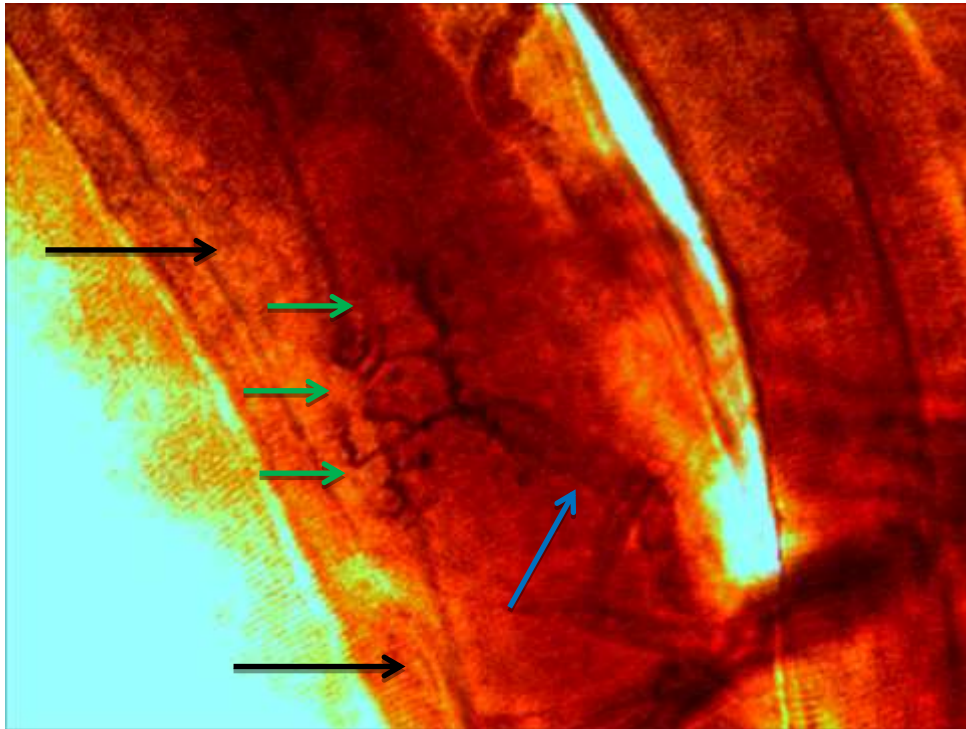


Fig (18) Isolated muscle fibers from Triceps at (30) day of diabetes induction showed fine demyelinated nerve fibers (← blue →), three motor ending (→ green) type end plate within partial degenerated muscle fibers (← black →) (silver nitrate stain 40X) .

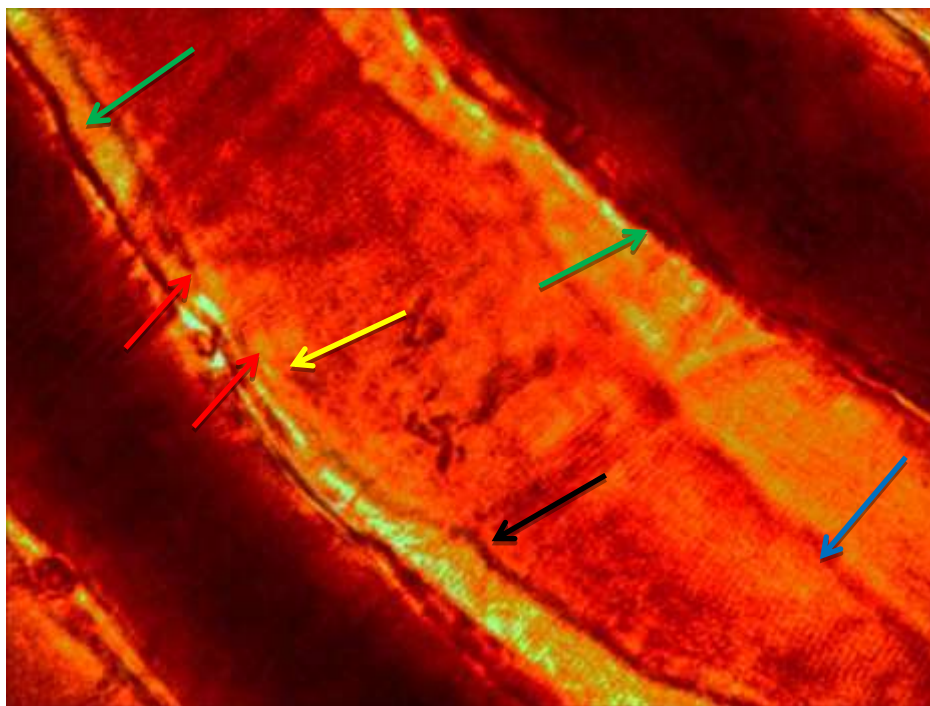


Fig (19) Isolated muscle fibers from Triceps at (30) day of diabetes induction showed atrophied muscle fibers (← blue →), dense connective tissue and inflammatory cell (→ green), discontinuous sarcolemma (← yellow →) demyelinated sensory nerve fibers (← red →) innervate the equatorial region of muscle spindle (← black →) (silver nitrate stain 40X) .



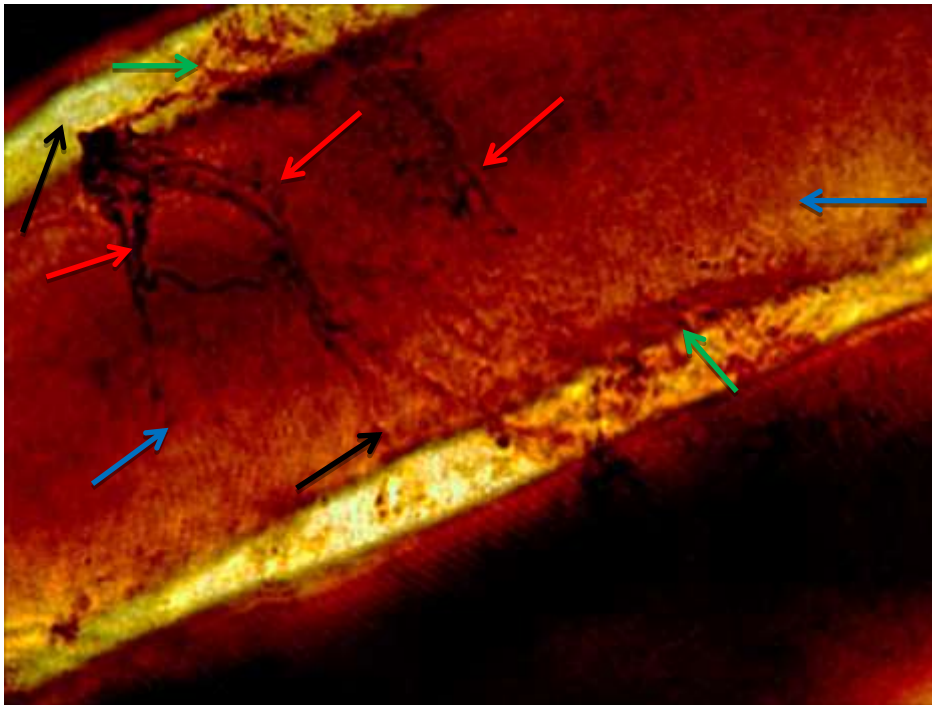


Fig (20) Isolated muscle fibers from Biceps at (45) day of diabetes induction showed degenerated muscle fibers (← blue →), heavy inflammatory cells (← green →) within intracellular space (← black →), ramifications (← red →) of nerve fibers , without obvious endings (← blue →) (silver nitrate stain 40X) .

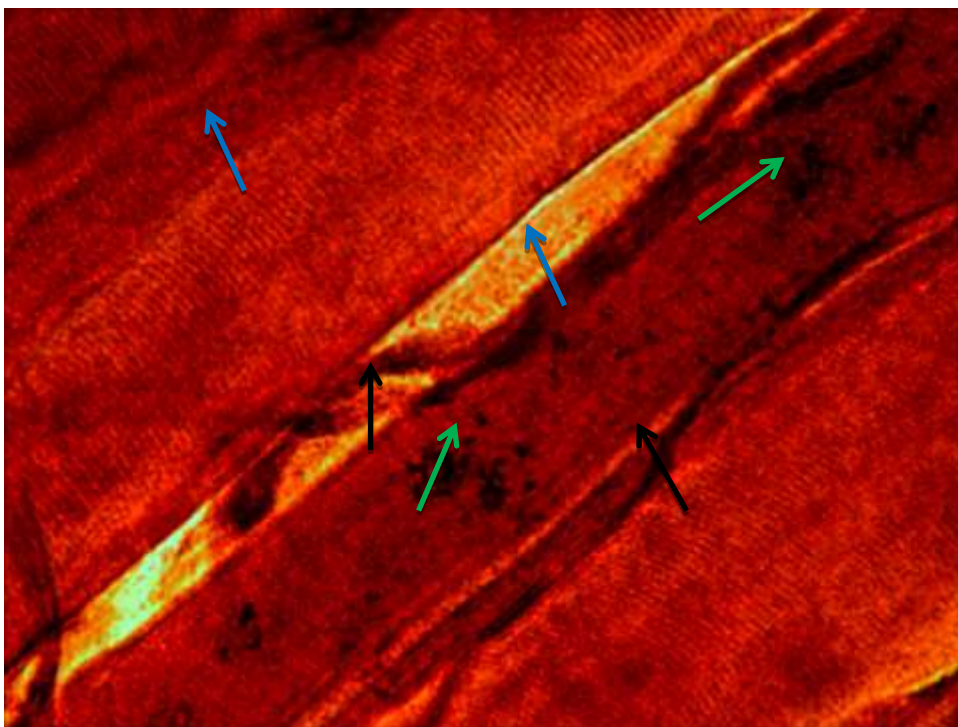


Fig (21) Isolated muscle fibers from Triceps at (45) day of diabetes induction showed myonecrosis (← black →), degenerated and retracted (← blue →) nerve endings , demyelination nerve fibers (← green →) (← blue →) (silver nitrate stain 40X).

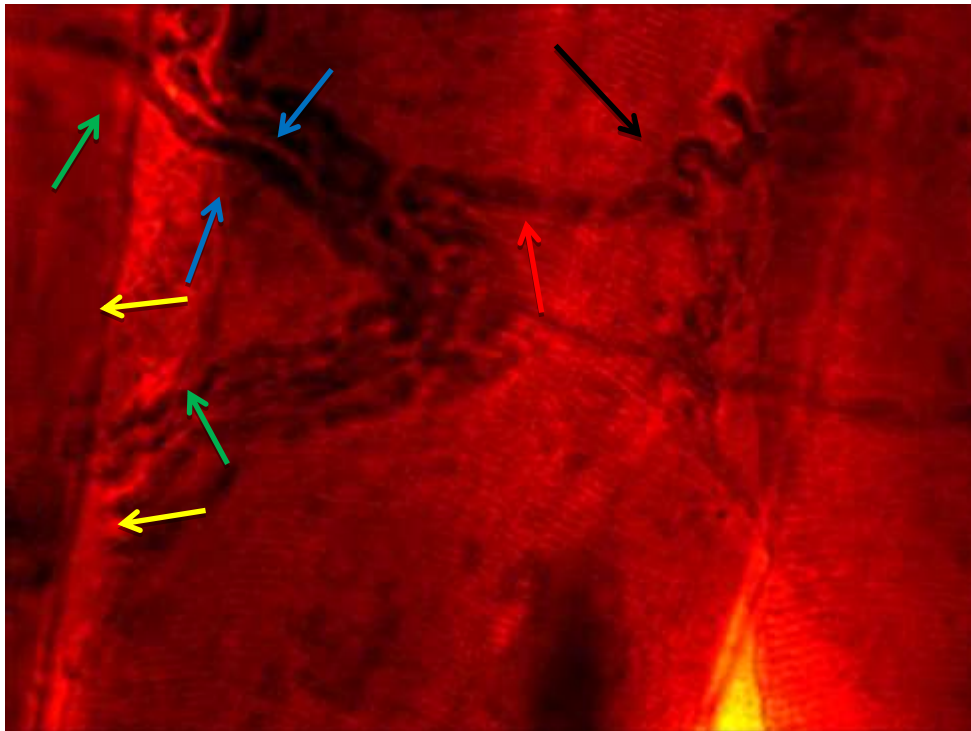


Fig (22) Isolated muscle fibers from Gastrocnemius at (45) day of diabetes induction showed thick myelinated axons (→), loss their myelin sheath (→) near the surface of muscle fibers (→) without endings , one nerve fibers (→) end with simple coiled ending (→) (silver nitrate stain 40X).

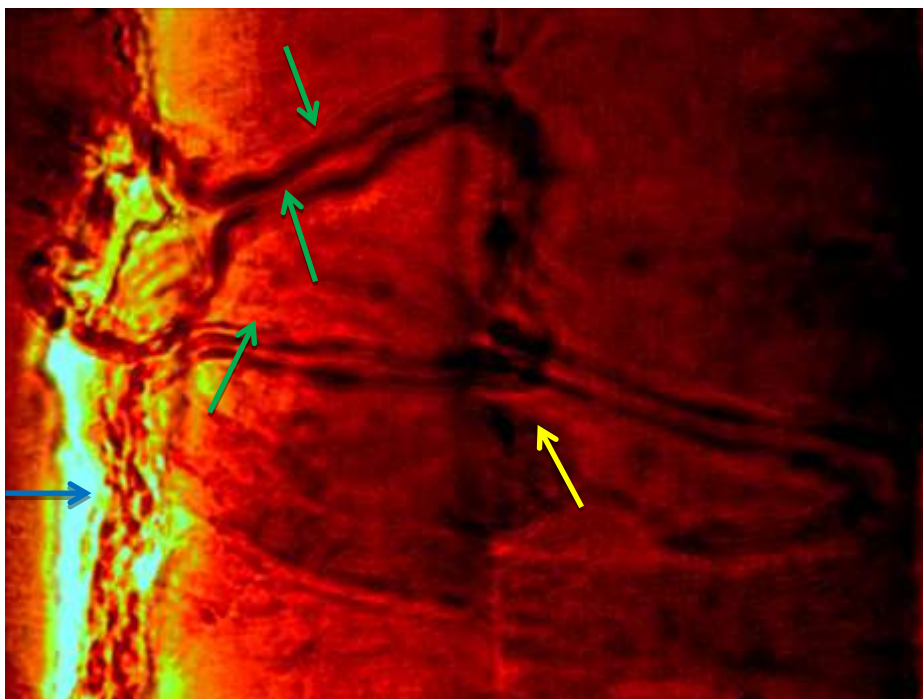


Fig (23) Isolated muscle fibers from Gastrocnemius at (45) day of diabetes induction showed stumps of nerve fibers (→), some of demyelinated (→), secondary terminal endings (→) (silver nitrate stain 40X) .






Fig (24) Isolated muscle fibers from Gastrocnemius at (45) day of diabetes induction showed degenerated equatorial region (→) of muscle spindle (→), mild cross striation (→) and simple motor ending (→) silver nitrate stain 40X).




Fig (25) Isolated muscle fibers from Triceps at (45) day of diabetes induction showed myelinated nerve fibers (→), schwann cell (→), retracted terminal branches (→), and simple motor endings (→) silver nitrate stain 40X).







Fig (26) Isolated muscle fibers from Triceps at (45) day of diabetes induction showed variable motor terminals , some simple configuration (), retracted motor end plate () and sprouting endings () no contact with normal nerve fibers (silver nitrate stain 40X) .

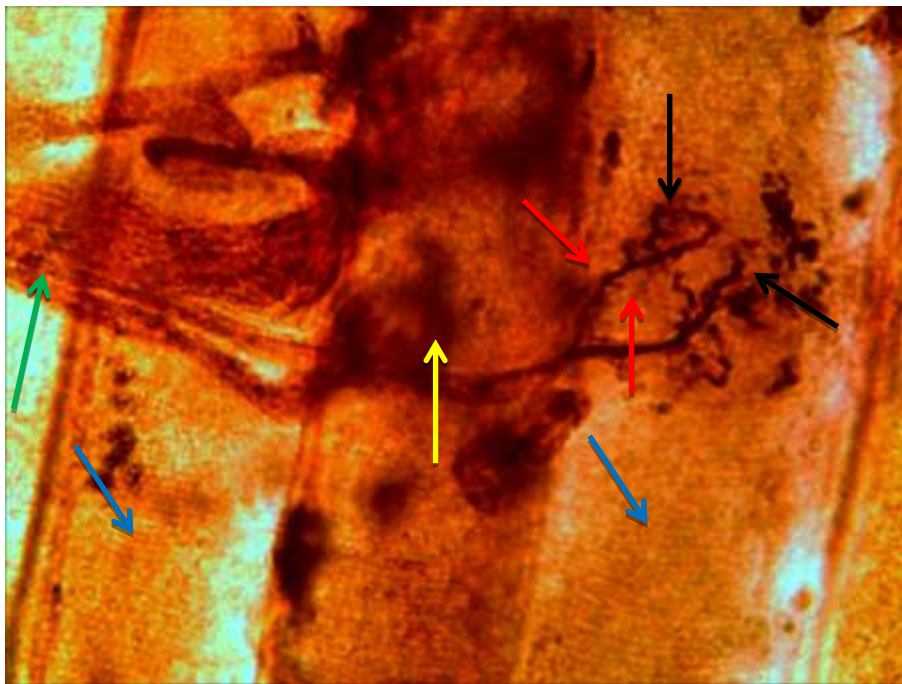







Fig (27) Isolated muscle fibers from Triceps at (45) day of diabetes induction showed degenerated muscle fibers (), intramuscular nerve trunk (), demyelinated nerve fibers (), bifurcate into two () branches , end with fine tapered endings () (silver nitrate stain 40X) .



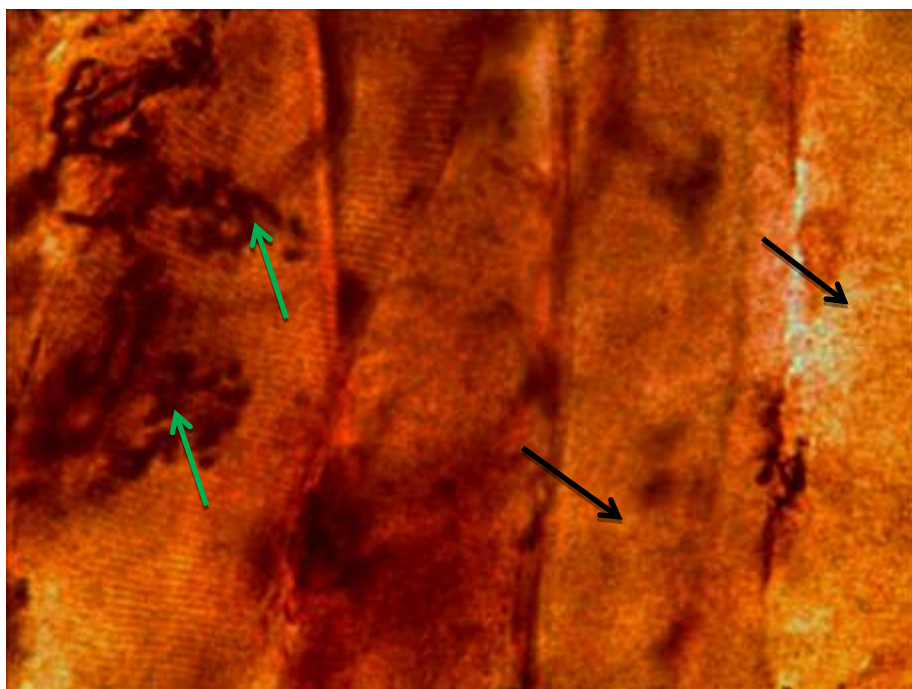





Fig (28) Isolated muscle fibers from Triceps at (45) day of diabetes induction showed structure of motor end plate (), hypertrophied motor terminals (), myonecrosis () (silver nitrate stain 40X) .

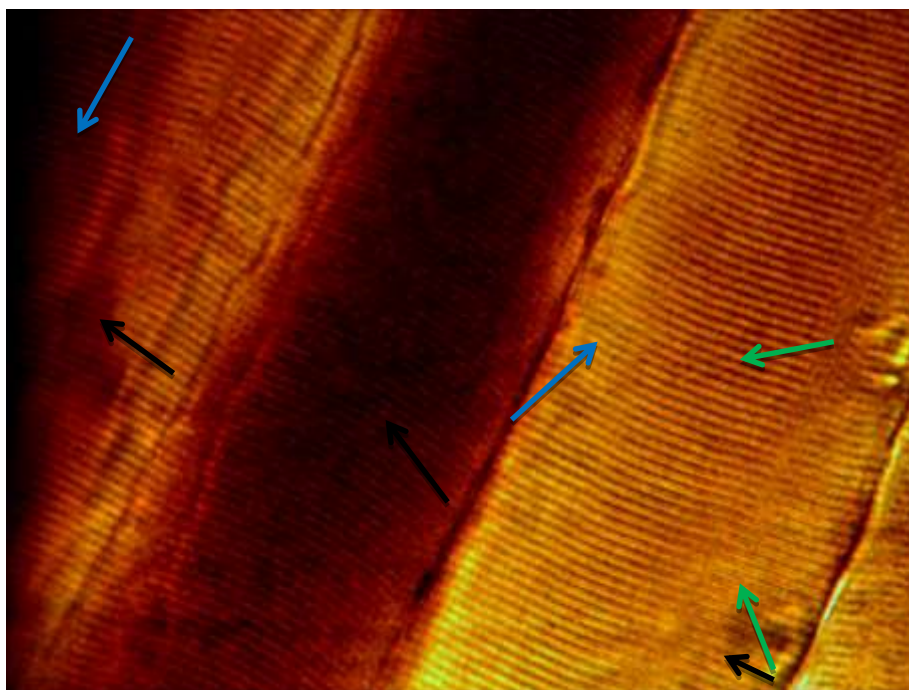





Fig (29) Isolated muscle fibers from Gastrocnemius at (15) day of diabetes induction and treated with arginine showed muscle fibers () with cross striations , normal **Z-line** () and normal regular sarcolemma () silver nitrate stain 40X) .

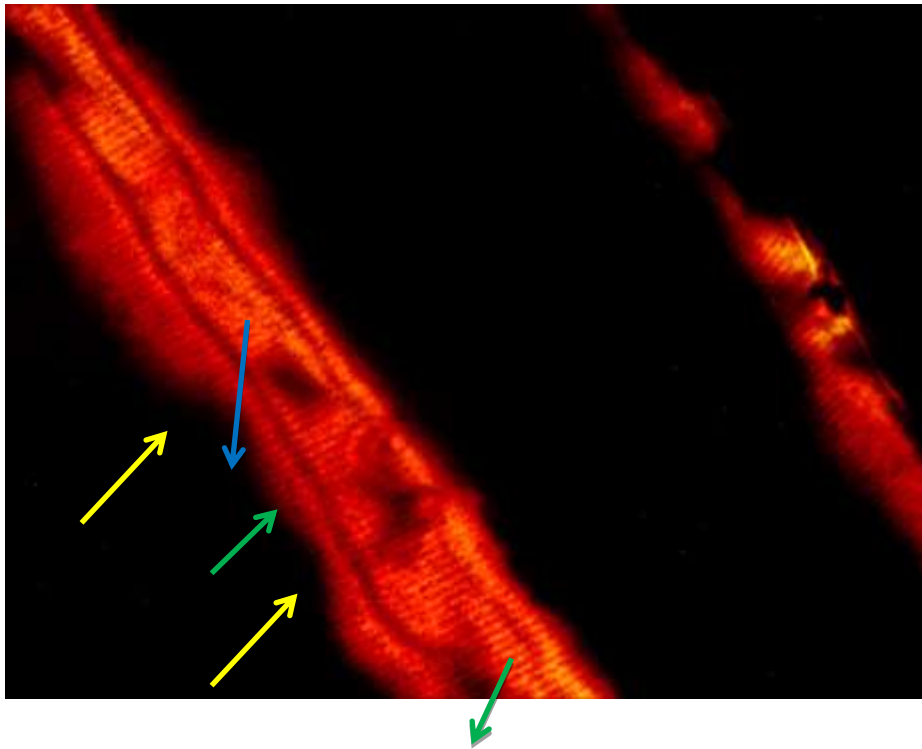


Fig (30) Isolated muscle fibers from Gastrocnemius at (15) day of diabetes induction and treated with arginine showed normal myotube (———→) with central arranged myonuclei (———→) and clear sarcolemma (———→) (silver nitrate stain 40X).

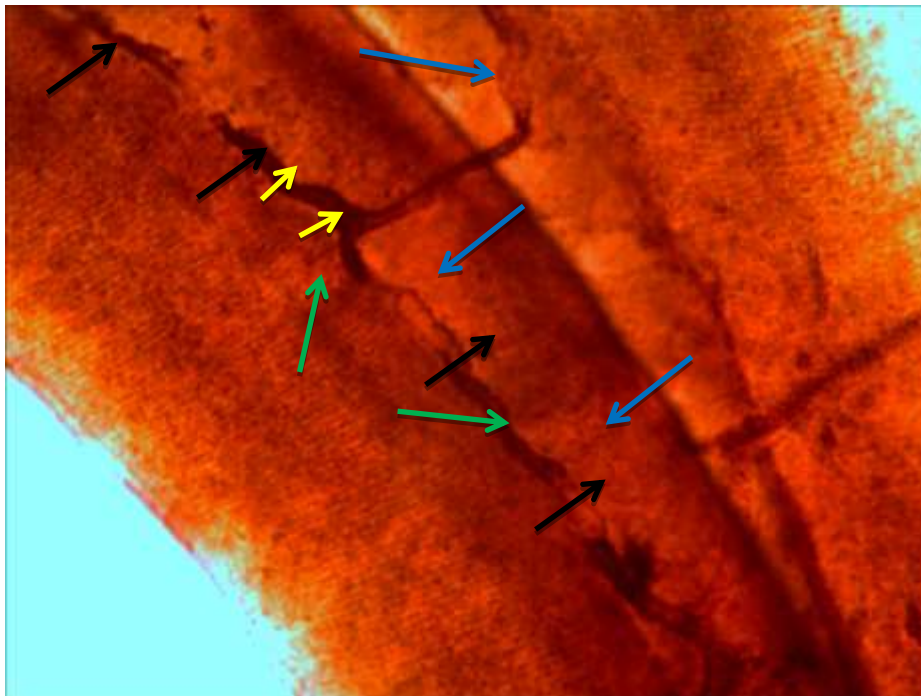


Fig (31) photograph on muscle fibers isolated from Triceps at (15) day of diabetes induction and treated with arginine showed segmented demyelination (———→), neuromuscular contact (———→), and primary branches (———→), along muscle fiber surface (———→) (silver nitrate stain 40X) .

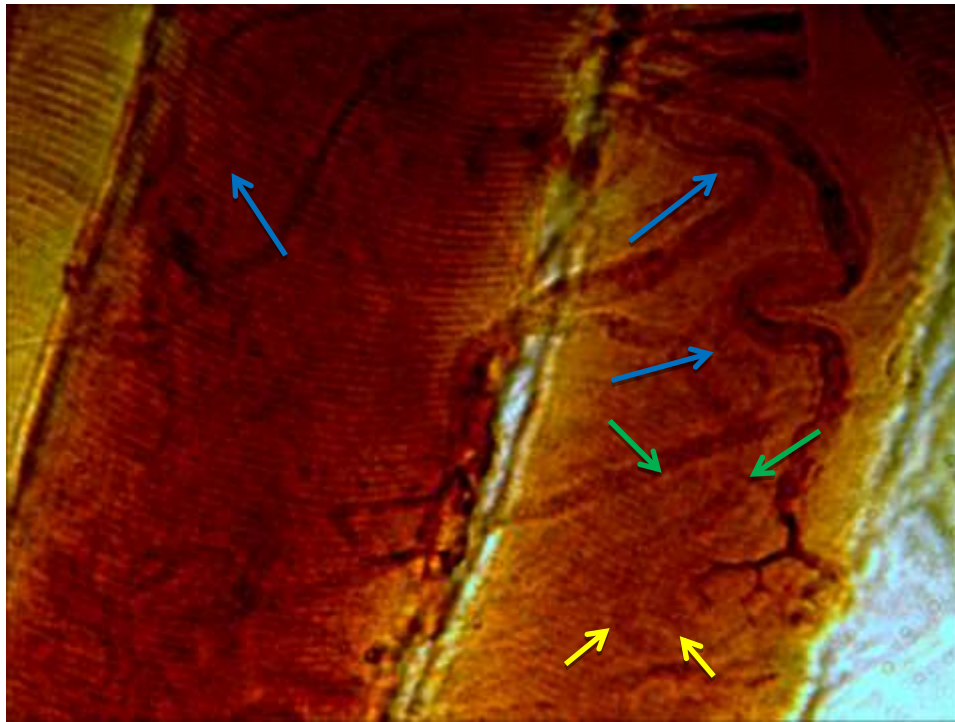


Fig (32) photograph on Isolated muscle fibers from Biceps at (15) day of diabetes induction and treated with arginine showed variable myelinated nerve fibers (→), primary motor ending (→), end with tapers fine endings (→) (silver nitrate stain 40X) .

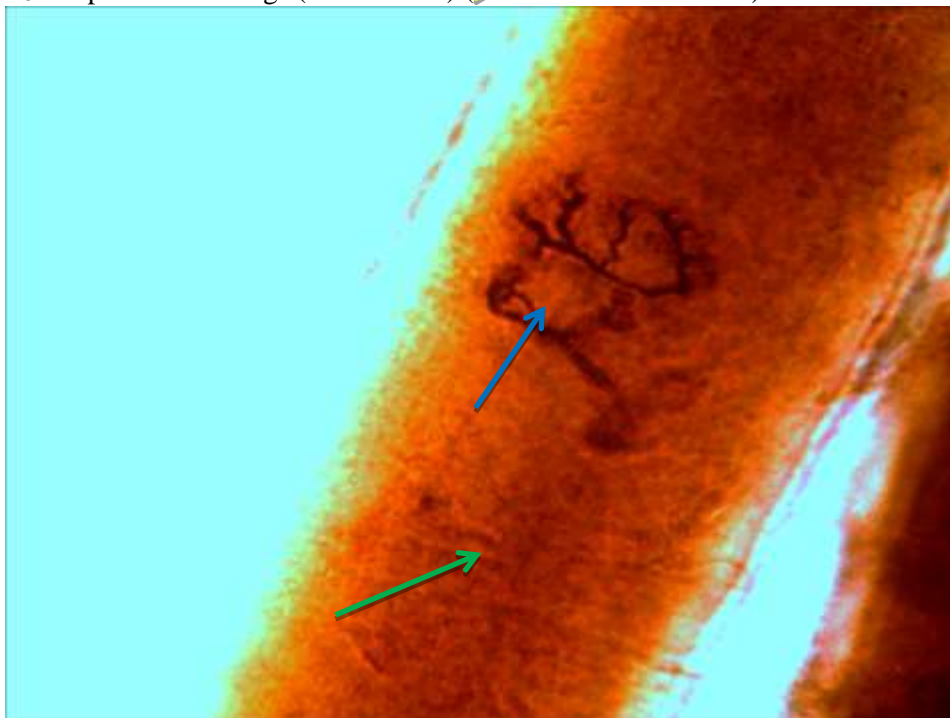


Fig (33) Isolated muscle fibers from Triceps at (15) day of diabetes induction and treated with arginine showed secondary nerve endings (→), still lost their contact with motor nerve fibers, partial degenerated muscle fibers (→) (silver nitrate stain 40X)

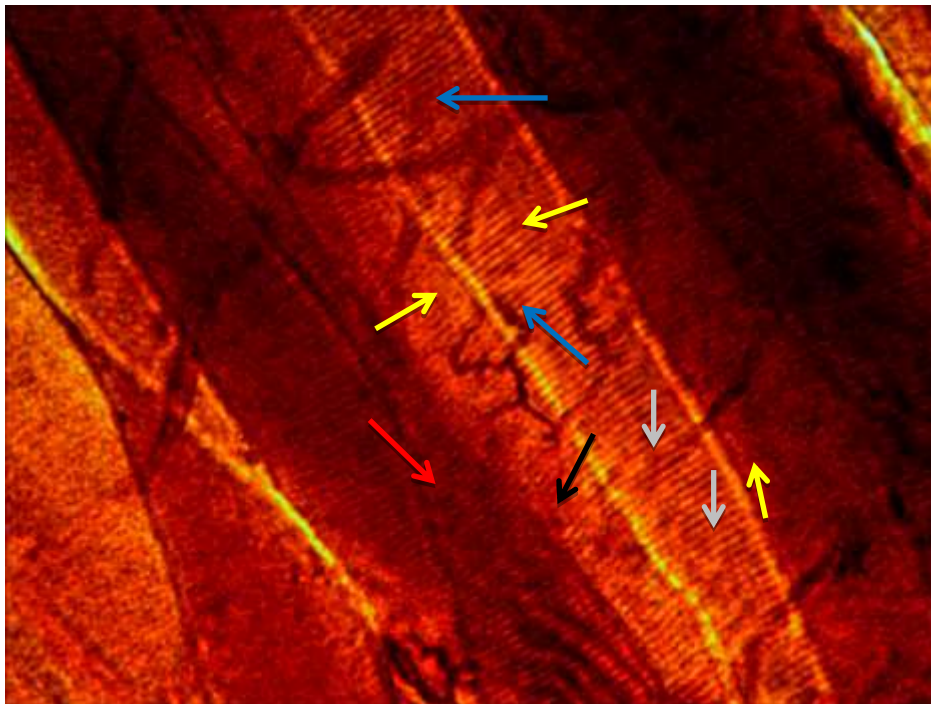








Fig (34) Isolated muscle fibers from Biceps at (30) day of diabetes induction and treated with arginine showed number of axons (), myelinated nerve fibers (), motor terminals (), stump of nerve fibers (), vesicular terminal () inflammatory cells () (silver nitrate stain 40X)

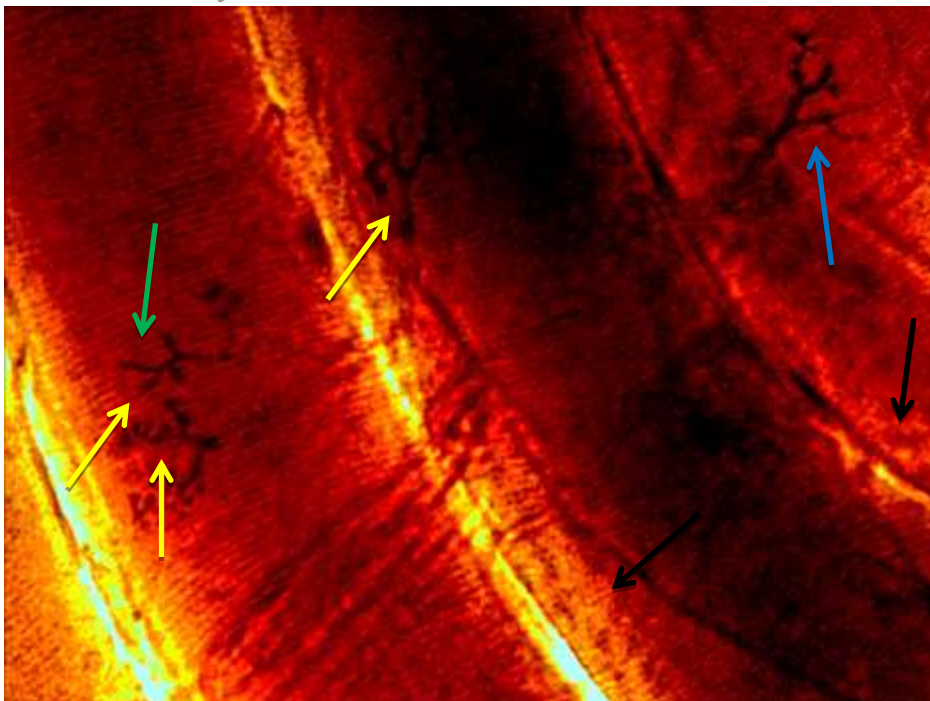






Fig (35) Isolated muscle fibers from Biceps at (30) day of diabetes induction and treated with arginine showed motor end plates endings (), secondary endings (), and some retracted endings (), myonecrosis fibers () (silver nitrate stain 40X)

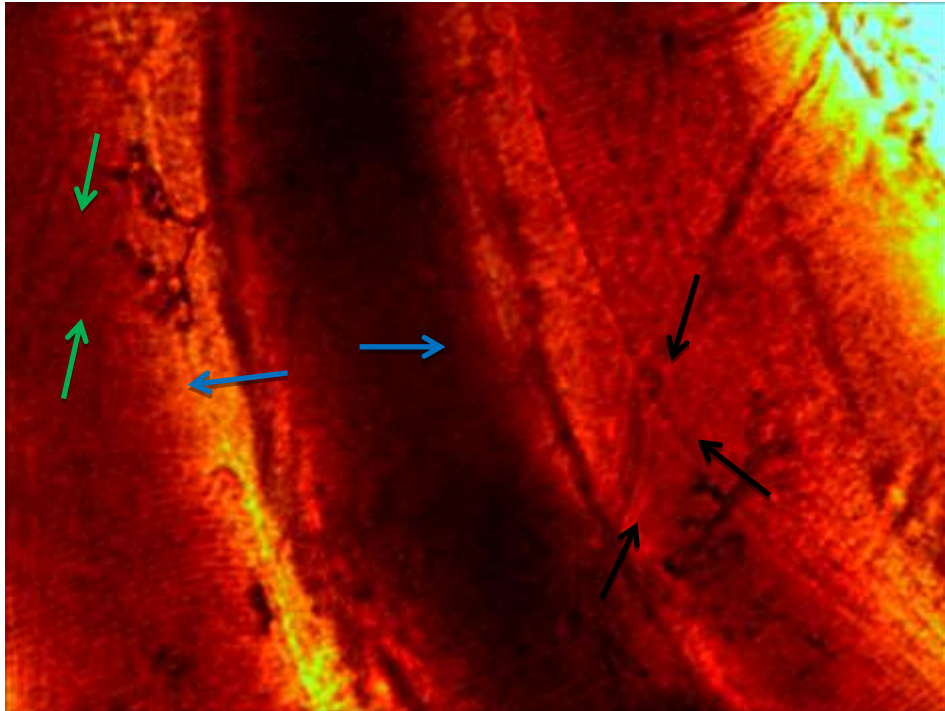





Fig (36) Isolated muscle fibers from Biceps at (30) day of diabetes induction and treated with arginine showed normal sarcolemma (), two motor end plate ending () and other retracted terminal end () (silver nitrate stain 40X) .

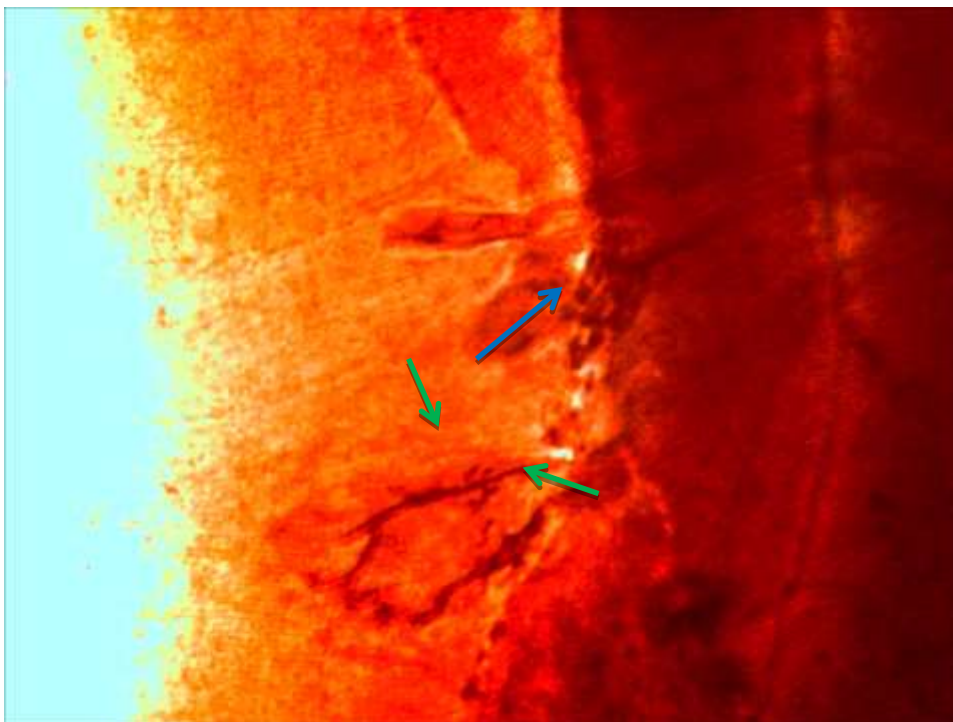




Fig (37) Isolated muscle fibers from Gastrocnemius at (30) day of diabetes induction and treated with arginine showed very well developed motor end plate ending (), with dense granules , other retracted ending () (silver nitrate stain 40X)

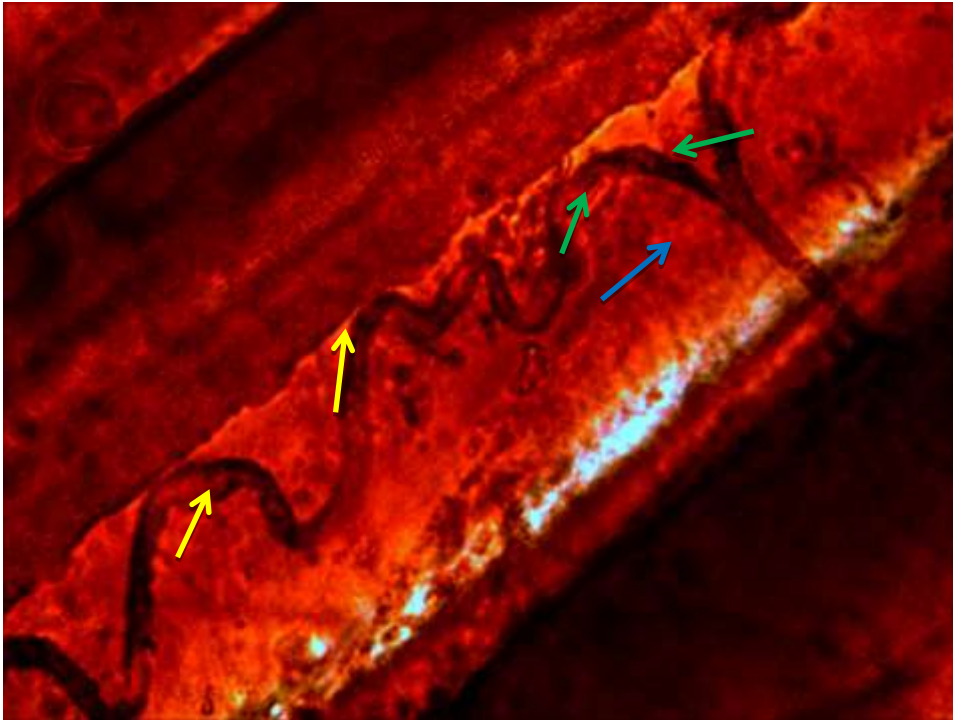


Fig (38) Isolated muscle fibers from Triceps at (30) day of diabetes induction and treated with arginine showed normal myelinated nerve fibers (blue arrow), bifurcate into two branches (green arrow), one extend (yellow arrow) along the muscle fiber (silver nitrate stain 40X)

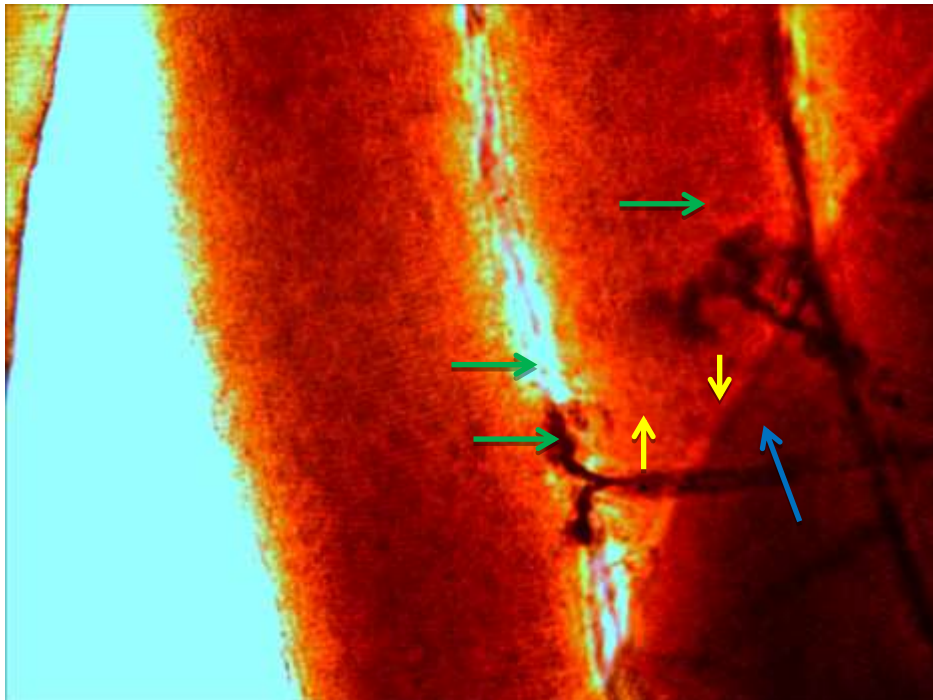


Fig (39) Isolated muscle fibers from Triceps at (30) day of diabetes induction and treated with arginine showed normal myelinated nerve (blue arrow), very well developed motor end plate (green arrow), presence myelination (yellow arrow) (silver nitrate stain 40X)



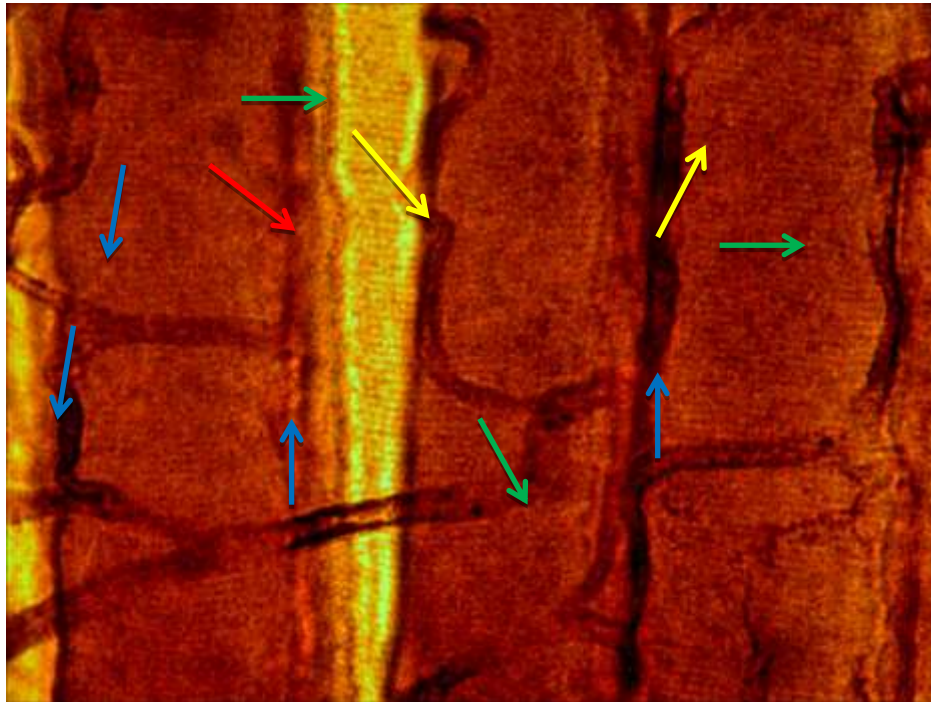






Fig (40) photograph on Isolated muscle fibers from Biceps at (45) day of diabetes induction and treated with arginine showed more normal myelinated fibers (), increased number of neural contact (), normal regular muscle fibers (), and normal intercellular space () between the muscle fibers (silver nitrate stain 40X)

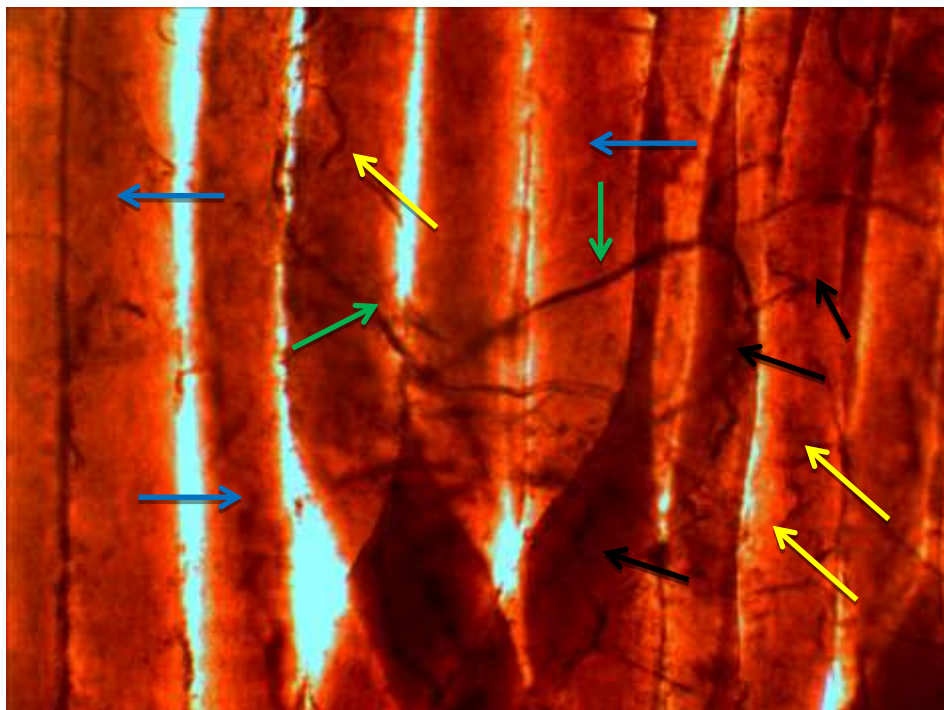






Fig (41) photograph on Isolated muscle fibers from Gastrocnemius at (45) day of diabetes induction and treated with arginine showed isolated muscle fibers (), large number of axons branches (), some twigs on and around muscle fibers (), and number of terminals endings () (silver nitrate stain 10X)

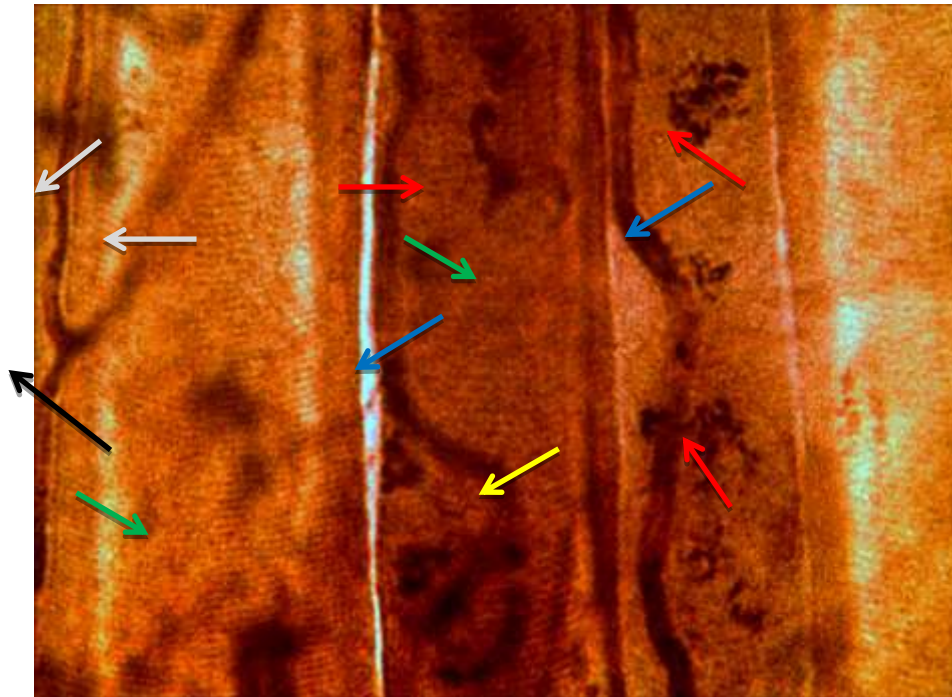


Fig (42) photograph on Isolated muscle fibers from Triceps at (45) day of diabetes induction and treated with arginine showed myelinated nerve fibers (→), normal muscle fibers (→), secondary ending (→), motor end plate (→) and myelin nerve fiber bifurcate (→) into two primary branches (→), within single muscle fiber (silver nitrate stain 40X)

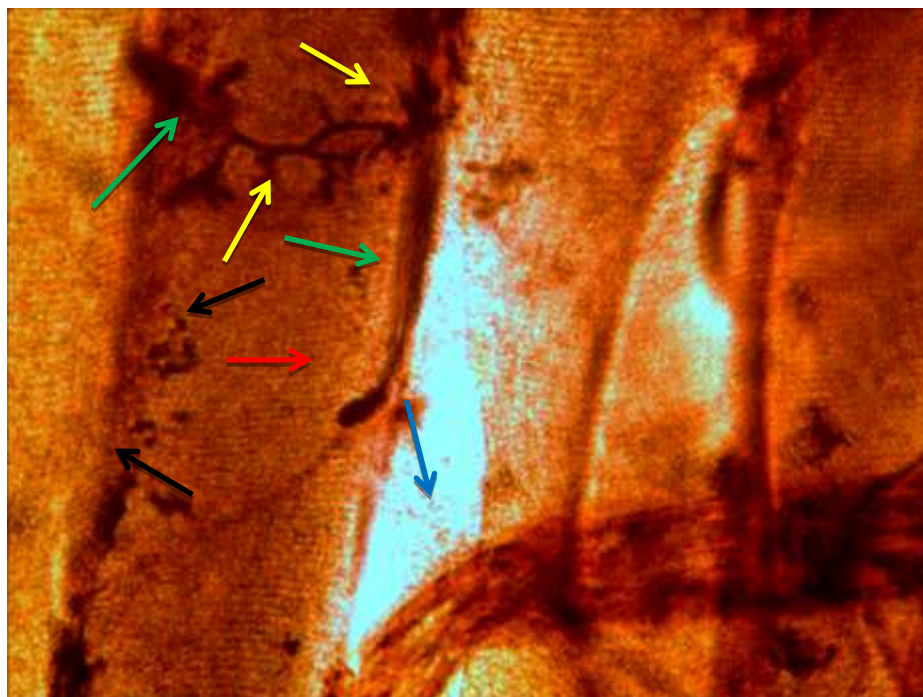


Fig (43) photograph on Isolated muscle fibers from Triceps at (45) day of diabetes induction and treated with arginine showed nerve trunk (→), myelin fibers (→), grapple like motor ending (→), other vesicular ending (→) and some remnant of degenerated motor endings (→) (silver nitrate stain 40X) .

Discussion

The study indicated that all muscle fibers that isolated from Triceps ,Biceps and Gastrocnemius skeletal muscles impregnated with silver nitrate and related to control rats showed normal , cylindrical tubes with tapers endings , with striations and peripheral myonuclei , all muscles supplied with intramuscular nerve trunk from plexus and stumps extend in the muscle connective tissue as myelinated and non-myelinated fibers which subdivided into terminal branches ends as motor end plate , secondary endings and these results may be related to the technique used in this study that the silver impregnation method have the advantage to visualized the nerve fibers as dark brown bundles stained more dense than the muscle fibers , in addition we can distinguished the nerve endings with the muscle fibers .

These results in agreement with previous studies clarified that the quality of impregnation is equally good for small and large nerve fibers bundles , single fibers both thick and thin and nerve terminals both motor and sensory , there was enough contrast to differentiate between nerve and muscle fibers , the non-neural structures like myonuclei , red blood cells , adipose tissue , connective tissue and walls of blood vessels may also impregnated but the most was the tissues neural elements which recognizable clearly by their dark stain (Walton , 1988 ; Al-mallak M. , 1992; Hirsch , 2007; Hassani M., 2013).

Ruff, (2003) reported that each myelinated motor axon reaches its target muscle subdivided to un-myelinated terminals fibers which form motor end plates , these terminal fibers contain potassium (K^+) and sodium (Na^+) channels ,that regulate the period and action potential amplitude .

The present study focuses primarily on the pathogenicity of diabetes induction on skeletal muscles and their nerve supplied at (15 , 30 , 45) days post (DM) induction, there was pathological changes at (15) days like focal degeneration crowded myonuclei, folded sarcolemma, loss of cross striations , each muscle fiber supplied with thick myelin fiber ends with irregular, tortuous nerve fibers and difficult to differentiate the motor and sensory axons, sever degree of histological changes noticed at (30) days post (DM) induction, partial degeneration of muscle fibers , infiltration of inflammatory cells, discontinuity of sarcolemma , primary and secondary endings was destroyed , the abnormalities consisted of increased number of end plates and formed complexity branched terminal axons. Also post (45) days of (DM) induction , finding showed sever degeneration , hemorrhage , thick and

interrupted sarcolemma along muscle fiber surface, segmented demyelination , the motor innervation was abnormal , increased number of un-well developed motor endings , there was heavy contribution among nerve fibers that supplied the muscle fibers , these changes that associated with (DM) may be related to the toxicity of (STZ) which used for (DM) induction and to the complications caused by (DM) it self , effect of (Ros) and increased (NO) that was lead to changes in blood vessels structure , reduced blood flow , the damaged of cellular structures or its direct effect on peripheral nervous tissues and the hyperglycemia that caused muscle fibers injury .

These results supported by other studies indicated that diabetic peripheral neuropathy affect the most patients with (DM) and to non-traumatic lower limb amputations and to contribution of high level of glucose to the pathogenesis of microvasculature complications in T1 and T 2 diabetes (Adler *et al.*, 2004 ; Aaron P. & Rodica, 2005).

Moreover (DM) associated with hyperglycemia produced long-term harm and failure of various tissues specially neural damage induced by diabetes and it is a dominant form of neuropathy , the alteration of neuromuscular transmission would contribute to the progressive impairment of extensor and flexor muscles through diabetes (Calcutt *et al.*, 2009 ; Carmen *et al.*, 2012).

In diabetic patients hyperglycemia was the major factor of diabetic neuropathy induced oxidative stress through diverse cellular pathways like raising aldose reductase activity , glycation end products and changing protein kinase activity (Zangiabadi *et al.*, 2011).

Various studies have proposed that oxidative stress was the main factor impairing ganglia and sensory nerves (Arora *et al.*, 2008 ; Sharma *et al.*, 2009).

The correlation between hyperglycemia and the development of a clinically detectable neuropathy has been well documented , diabetic neuropathy is an heterogeneous disorder has different syndromes depending on the nerve fiber type such as great fiber neuropathies may include sensory or motor nerves (Fazan *et al.*, 2010).

Our findings identified variable nerve endings most of appeared ramified , irregular and showed retracted extend within degenerated muscle fibers , these endings related to segmented demyelinated nerve fibers in all muscles related to

diabetes rats at each period (15 , 30 , 45) days post (DM) induction this may be related to metabolic disorder caused by diabetes which lead to complications like myelin destruction , reduced in growth factors and axons atrophy , these results was obtained by other investigators who confirmed that interactions between various direct and indirect metabolic consequences of insulin lack, hyperglycemia and environmental factors are required to the emergence of diabetic, neuropathies , axonal abnormality resulted from the metabolic derangement , decrease in axonal transport of structural proteins after (4)weeks after (STZ) injection , most changes were performed in limb nerves which more susceptible to injury (Harati , 2007 ; Fazan *et al.*, 2010) .

Previous study by Thomas *et al.*, (1990) reported a reduction of the myelin thickness mainly on the small myelinated fibers of the tibial nerves in chronic STZ-diabetic rats especially if the induction of diabetes was at early stages of life .

Furthermore morphological changes of the autonomic nervous system in diabetes , either in human or rats are recorded to be associated with degenerative process showed in the nervous fibers and their myelin sheaths , morphological and electrophysiological studies propose that the axons was the initial site of harm in the peripheral nerves (Yasaki & Dyck , 1990 ; Saini *et al.*, 2007) .

Results and figures from recent work determined the role of arginine (arg) on diabetes pathogenicity and its effect on skeletal muscles with their nerve supplies in diabetes rats at each period (15,30,45) days post diabetic induction , Results showed some muscle fibers with normal striations , less degeneration, new myotubes formation at (15) days post (DM) induction , moreover the photograph on isolated muscle fibers from whole muscle impregnated with silver revealed to more muscle integrity , most fibers with cross striations , normal intercellular space between muscle fibers , each muscle fibers supplied with myelinated nerve fibers extend from nerve trunk and variable motor endings such as conical , vesicular and motor -end plate , also at (45) days period the results confirmed less degeneration , normal appearance of muscle spindle , myelinated nerve fibers , normal vesicular myonuclei , regenerated myotubes , well developed endings , normal distribution of these endings on each muscle fibers and variable shape and size of endings like primary , secondary and grape-like motor endings , these results may be confirmed the role of (arg) as amino acid agent reduced the harmful effects associated with

diabetes and (STZ) metabolites , act on glucose metabolism , repairing nerves damage and have protective role diabetes neuropathy .

These results in agreement with other studies described the role of (arg) for activating nitric oxide (NO) , the most supplements for nerve health use as vasodilation and to increase (NO) level and this mediated vasodilation will raise delivery of oxygen and nutrients to poorly, perfused nerves to re-establish their normal membrane potential , moreover (NO) and certain amino acids interact with schwann cells to trigger biological responses (Salvatore *et al.*, 2011).

Arginine wanted for the creatine synthesis, an essential energy source to muscle contraction , also (arg) induced (No) production by endothelial cells, which contribute to raise blood flow and then glucose and amino acid uptake by skeletal muscle and (No) it self induced both transport and oxidation of glucose by skeletal muscle, also (No) physiological concentrations may inhibit proteolysis of muscle (Omnia *et al.*, 2014).

References

Aaron, P. Kellogg & Rodica pop-busui (2005). Peripheral Nerve Dysfunction in Experimental Diabetes Is Mediated by Cyclooxygenase-2 and Oxidative Stress, Antioxidants & Redox Signaling. Vol.:7. No.: 11-12.

Adler, M. ; Manley, HA. ; Purcell, AL. ; Deshpande, SS. ; Hamilton, TA. ; Kan, RK. ; Oyler, G. ; Lockridge, O. ; Duysen, EG. & Sheridan, RE.(2004). Reduced acetylcholine receptor density, morphological remodeling, and butyrylcholinesterase activity can sustain muscle function in acetylcholinesterase knockout mice. Muscle Nerve. 30(3). Pp :317-27.

Al- Malaak M.K. (1992) . Descriptive study on bat muscle spindle . MSc thesis .Basrah university .

Arora, M. ; Kumar, A. ; Kaundal, R.K. & Sharma, S.S. (2008) Amelioration of neurological and biochemical deficits by peroxynitrite decomposition catalysts in experimental diabetic neuropathy. Eur J Pharmacol. 596(1-3). Pp:77-83..

Barbosa, T.C. ; Jiang, L.Q. ; Zierath , J.R. & Nunes, M.T. (2013) . L-Arginine enhances glucose and lipid metabolism in rat L6 myotubes via the NO/ c GMP pathway. Metabolism clinical and Experimental. Vol.: 62 . Pp: 79-89.

Barker, D. & Ip, M.C. (1963). A silver method for demonstrating the innervation Of mammalian muscle in teased preparations. *J. Physiol. Lond.* 169. Pp : 73-74P.

Calcutt, NA. ; Cooper, ME. ; Kern, TS. & Schmidt, AM. (2009) A silver method for demonstrating the innervation Of mammalian muscle in teased preparations. *Nat Rev Drug Discov* 8. Pp: 417-429.

Cameron, N. ; Eaton, S.E. ; Cotter, M.A.&Tsfaye, S. (2001) Vascular factors and metabolic interactions in the pathogenesis of diabetic neuropathy, *Diabetologia* .44(11) . Pp:1973-88.

Carmen,C. Garcia ; Joseph, G. Potian ; Kormakur Hognason ; Baskaran Thyagarajan ; Lester, G. Sultatos ; Nizar Souayah ; Vanessa, H. Routh & Joseph, J. McArdle (2012) Acetylcholinesterase deficiency contributes to neuromuscular junction dysfunction in type 1 diabetic neuropathy. *Am J Physiol Endocrinol Metab*303 . Pp: E551–E561 .

Forstermann, U.& Sessa, W.C. (2012). Nitric oxide synthases: regulation and function. *Eur. Heart J.*33 . Pp : 829-837.

Harati, Y. (1987) Diabetic peripheral neuropathies. *Ann Intern Med* 107. Pp: 546-559 .

Harati, Y. (2007). Diabetic neuropathies: unanswered questions. *Neurol.Clin.* 25(1). Pp : 303-17.

Hassani M. K.(2013) . Histopathological, Histochemical and Biochemical aspects on myotoxicity induced by Drug (Bupivacaine) in skeletal muscles of experimental rats males *Rattus norvegicus*. MSc thesis. Basrah university.

Hirsch, NP. (2007) Neuromuscular junction in health and disease. *Br J Anaesth* 99(1). Pp : 132-138.

Ki Chul Choi , M.D. ; Seong Cheol Le e , M.D. ; Soo Wan Kim , M . D. ; Nam Ho Ki m , M.D. ; Jong-Un Le e , M.D. & Young Joon Kang ,M.D. (1999) Role of Nitric Oxide in the Pathogenesis of Diabetic Nephropathy in Streptozotocin Induced Diabetic Rats. *The Korean Journal of Internal Medicine* . Vol. : 14 . No. : 1.

Loscalzo, J. & Welch, G. (1995). Nitric oxide and its role in the cardiovascular system. *Prog. Cardiovasc. Dis.* 38. Pp : 87–104.

Mayer, JH. & Tomlinson, DR. (1983) Axonal transport of cholinergic transmitter enzymes in vagus and sciatic nerves of rats with acute experimental diabetes mellitus: correlation with motor nerve conduction velocity and effects of insulin. *Neuroscience* 9 . Pp:951-957.

Omnia Aly ; Dina Abo El-Matty ; Ehsan Aly Badawy ; Hanna Wafaay El Sherif & Hoda Aly Megahed (2014) . Regulation of Hyperglycemia and Dyslipidemia by Exogenous L-Arginine in Streptozotocin-induced Diabetic Rats, *Global Journal of Pharmacology* 8 (4) . Pp : 525-531.

Picard, EH. & De La Monte, SM. (1987) A 68 year old man with diabetes mellitus and progressive muscle weakness. *N Engl J Med* 316 . Pp: 1326–1335 .

Ruff, RL.(2003) Neurophysiology of the neuromuscular junction: overview. *Ann N Y Acad Sci* . 998. Pp: 1–10.

Saini, A.K. ; Arun, K.H.S. & Sharma, S.S. (2007) Preventive and curative effect of edaravone on nerve functions and oxidative stress in experiment diabetic neuropathy. *Eur. J. Pharmacol.* 568. Pp: 164-172.

Salvatore, E. ; Rinaldi C. ; Tucci T. et al., (2011). Growth hormone response to arginine test differentiates between two subgroups of Huntington's disease patients. *J. Neurol. Neurosurg. Psychiatry* 82. Pp :543-547.

Schmeichel, A.M. ; Schmelzer, J.D. & Low, P.A. (2003) Oxidative injury and apoptosis of dorsal root ganglion neurons in chronic experimental diabetic neuropathy. *Diabetes.* 52. Pp: 165-171.

Sharma, S.S. ; Kumar, A. ; Arora, M. & Kaundal, R.K. (2009) Neuroprotective potential of combination of resveratrol and 4-amino 1,8 naphthalimide in experimental diabetic neuropathy: Focus on functional, sensorimotor and biochemical changes. *Free Radical Res.*, 43. Pp: 400-408.

Srivastava, S.K. ; Ramana, K.V. & Bhatnagar, A. (2005) Role of aldose reductase and oxidative damage in diabetes and the consequent potential for therapeutic options. *Endocrine Rev.* 26: 380-392.

Sugimoto, K. ; Yasujima,V. & Yagihashi, S. (2008) Role of advanced glycation end products in diabetic neuropathy. *Curr. Pharm. Design.* 14. Pp: 953-961.

Thomas, P. K.; Fraher, J. P.; O'Leary, D.; Moran, M. A.; Cole, M. & King, R. H.(1990) Relative growth and maturation of axon size and myelin thickness in the tibial nerve of the rat. 2. Effect of streptozotocin-induced diabetes. *Acta. Neuropathol.* 79. Pp: 375-86 .

Valéria Paula Sassoli Fazan; Carlos Augusto Carvalho de Vasconcelos; Marcelo Moraes Valença; Randy Nessler & Kenneth Charles Moore (2010) . Diabetic Peripheral Neuropathies: A Morphometric Overview. *Int. J. Morphol.* 28(1). Pp: 51-64 .

Walton, W. J. N. (1988). The anatomy and physiology of the motor unit. In : Disorders of voluntary muscle. 5nd ed. Edinburgh, Churchill,Livingston.

Woolf, AL. & Manlis, JM. (1957) Changes in the intramuscular nerve endings in diabetic neuropathy: a biopsy study .*J Pathol Bacteriol* 73 . Pp: 316–318.

Yamagishi, S.I. ; Ogasawara, S. ; Mizukami, H. ; Yajima, N. & Wada, R. et al. (2008) Correction of protein kinase C activity and macrophage migration in peripheral nerve by pioglitazone, peroxisome proliferator activated- γ -ligand, in insulin-deficient diabetic rats. *J. Neurochem.* 104 . Pp : 491-499.

Yasaki,S. & Dyck, PJ.(1990) Duration and severity of hypoglycemia needed to induce neuropathy. *Brain Res.* 531. Pp:8-15.

Zangiabadi, N. ; Sheibani, V. ; Asadi-Shekaari, M. ; Shabani M. & Jafari, M. et al., (2011) Effects of melatonin in prevention of neuropathy in STZ induced diabetic rats. *Am. J. Pharmacol. Toxicol.* 6 . Pp: 59-67.

Zangiabadi, N. ; Ahrari, M.N. & Nakhaee, N. (2007) The effect of omega-3 fatty acids on Nerve Conduction Velocity (NCV) and f-wave latency in patients with diabetic polyneuropathy. *Am. J. Pharmacol. Toxicol.* 2. Pp: 1-3.

الخلاصة

صممت الدراسة للبحث في تأثير السكري المستحث على امراضية العضلة والعصب اضافة الى الدور المحتمل للارجنين كعامل يمنع مضاعفات السكري خلال الفترات (15 ، 30 ، 45) يوم بعد الاستحثاث.

اوجدت الدراسة اللامقطعية طريقة النقع بنترات الفضة للالياف العضلية المعزولة من العضلات الهيكلية التي تعود الى مجموعة السكري المستحث و المتمثلة بالعضدية الثنائية و الثلاثية الرؤوس و العضلة التوأمية عند الفترة (15) يوم بعد الحث تحلل قليل ، زيادة في الانوية العضلية ، مناطق تنخر ، اختزال في اقطار المحاور العصبية ، انكماش النهايات العصبية الحركية ، عدم تمايز للانوية في مناطق النهايات الصفائحية الحركية مع زيادة كثافة وسمك غشاء الليف العضلي و كانت التغيرات اكثر شدة بعد (30) يوم من الحث و اشارت النتائج الى تحلل الالياف العضلية ، عدم وضوح التخطيطات المستعرضة ، تغلظ الانوية ، فقدان تظهر عدم استمرارية *tortuous* و بعض المحاور ملتوية الالياف العصبية لمعظم اغمدتها النخاعينية ، غشاء الليف العضلي ، بينما اظهرت الياف عضلية معزولة من عضلات السكري عند الفتره (45) يوم بعد (، تقطع الاغمدة النخاعينية ، فقدان الحث اختزال شديد في اقطار الالياف العضلية ، عدم وجود الخط) بعض النهايات الحركية اتصالها مع الالياف العصبية الاصلية المجهزة لها و انكماش النهايات العصبية مقارنة مع الالياف العضلية المعزولة لعضلات تعود لمجموعة الجرذان المصابة بالسكري و معاملة مع الارجنين حيث اوضحت النتائج للفحص المجهرى الضوئي انتظام الالياف تخطيطات مستعرضة واضحة ، انوية محيطية ، تنخر المحاور العصبية المختصة لهذه الالياف العضلية ، هناك انابيب عضلية منخرة مع وجود محاور طرفية اولية ثانوية تنتهي بنهايات حركية متطورة تتنوع بالحجم و الشكل بعضها مخروطية ، تشبه الاغصان عند الفترتين (15 و 30) يوم بعد الحث و المعاملة مع الارجنين كما *configuration's* ، وتشكلات *twigs* اظهرت الالياف العضلية المعزولة بعد (45) يوم الياف عصبية معظمها منخعة وذات تخصصات على طولها ، *grape* . نهايات متنوعة بسيطة و ثانوية و اخرى تشبه العنقود .