



وزارة التعليم العالي والبحث العلمي
جامعة ميسان
كلية التربية الاساسية

Ministry of Higher Education and Scientific
Research
University of Misan
College of Basic Education

Misan Journal for Academic Studies
Humanities, social and applied sciences

مجلة ميسان للدراسات الأكاديمية العلوم الانسانية والاجتماعية والتطبيقية

ISSN (Print) 1994-697X
(Online)-2706-722X

المجلد 23 العدد 52 كانون الاول 2024
Dec 2024 Issue 52 Vol 23



مجلة ميسان للدراسات الأكاديمية

العلوم الإنسانية والاجتماعية والتطبيقية

كلية التربية الأساسية / جامعة ميسان / العراق

Misan Journal for Academic Studies

Humanities, social and applied sciences

College of Basic Education/University of Misan/Iraq

ISSN (Print) 1994-697X (Online) 2706-722X

المجلد (23) العدد (52) كانون الاول (2024)

DEC 2024 ISSUE52 VOL 23



OJS / PKP
www.misan-jas.com

IRAQI
Academic Scientific Journals



ORCID

OPEN ACCESS



journal.m.academy@uomisan.edu.iq

رقم الأيداع في دار الكتب والوثائق بغداد 1326 في 2009

| الصفحة | فهرس البحوث | ت |
|-----------|--|----|
| 15 – 1 | The Relationship Between Periodontitis Severity and MCP-1, IL-6 Levels in Gingival Crevicular Fluid Mohammed Faisal Ali Ghada Ibrahim Taha | 1 |
| 29 – 16 | Organizational Reflection and Its Impact on Strategic Performance: An Analytical Research in the General Company for Electrical and Electronic Industries Ayman Abdul Sattar Jasim Aamer Fadous Azib Al-Lami | 2 |
| 42 - 30 | Convolutional Neural Networks in Detection of Plant Diseases Shaymaa Adnan Abdulrahman | 3 |
| 57 - 43 | Gestural and Facial Expression Feedback in Motivating EFL Learners to Learn Grammar Inas Kamal Yaseen | 4 |
| 67 - 58 | The Effect of Titanium Oxide Nanotubes on the Surface Hardness of a Three-Dimensional Printed Denture Base Material Anwr Hasan Mhaibes Ihab Nabeel Safi | 5 |
| 81 - 68 | Myofunctional Appliance for Class III Malocclusion: A review Maryam S. Al-Yasari Layth M. Kareem Ihab N. Safi Mustafa S. Tukmachi Zahra S. Naji | 6 |
| 91 - 82 | The Intertwined Trajectory between Gender and Psychic Anxiety in Chimamanda Ngozi Adichie's Americanah Tahseen Ali Mhodar Hayder Ali Abdulhasan | 7 |
| 104 - 92 | The Role of Digital Human Resource Management Practices in Achieving Employee Well-being: An Analytical Study within the Civil Aviation Authority Ayman Kadhum Al-Qaraghoul Ali Hasson Al-Tae Sinan Fadhel Hamad | 8 |
| 113 - 105 | Employing the Frontload Vocabulary Strategies in Enhancing Iraqi EFL Students' Vocabulary Retrieval Abilities Aswan Fakhir Jasim | 9 |
| 122 - 114 | Assessment of the surface hardness of high-impact polymethylmethacrylate following long-term dipping in clove oil solution Karrar Salah Al-Khafagi Wasmaa Sadik Mahmood | 10 |
| 133 - 123 | Improved Machine Learning Techniques for Precise DoS Attack Forecasting in Cloud Security Yasir Mahmood Younus Ahmed Salman Ibraheem Murteza Hanoon Tuama wahhab Muslim mashloosh | 11 |
| 147 - 134 | The Impact of Using Menus Strategy on the Performance of Iraqi University Students in English as a Foreign Language in Writing Composition Ansam Ali Sadeq | 12 |
| 167 - 148 | Attitudes of students in the Department of General Science in the College of Basic Education towards electronic tests Shaimaa Jasim Mohammed | 13 |

| | | |
|-----------|--|----|
| 188 - 168 | The Systemic Heterogeneity in Adnan Al-Sayegh's Poetry – with Reference to Group (Text Dice) Abdulrahman Abdullah Ahmed | 14 |
| 198 - 189 | Legal Means Employed by the Iraqi and French Legislators to Deter Abuse of Office: A Comparative Study Mahdi Khaghani Isfahani Jaafar Shakir Hussein | 15 |
| 208 - 199 | Challenges of the social and structural identity in the Middle East (Iraq as a model) Yousif Radhi Kadhim | 16 |
| 226 - 209 | Evaluation of the Susceptibility of some Eggplant Varieties and the Role of Their Biochemical Compounds in Resistance to the Leafhopper <i>Amrasca biguttula</i> Fayroz T. Lafta Aqeel Alyousuf Hayat Mohammed Ridhe Mahdi | 17 |
| 241 - 227 | The Effect of Using Modern Technologies on the Interaction of Middle School Students in Geography Ali Fakhir Hamid | 18 |
| 252 - 242 | Narrative themes in the papers of Atyaf Sanidah, the novel (I may be me) as a mode Raad Huwair Suwailem | 19 |
| 272 - 253 | The Role of Composing the Soundtrack for the Dramatic Film (Psychopath): An Analytical Study Seerwan Mohammad Mustafa Abdalnaser Mustafa Ibrahim | 20 |
| 287 - 273 | The psychological connotations of poetic images in the poetry of Rahim Al-Gharabawi Salam Radi Jassim Al-Amiri Mehdi Nasserri Haider Mahallati | 21 |
| 311 - 288 | Pedagogical Knowledge Competencies Among Students/Teachers in the Mathematics Department and Their Relationship to Professional Motivation Duha Hamel Hussei Haider Abdel Zahra Alwan | 22 |
| 323 - 312 | Derivatives in douaa Alahad: a semantic morphological study Zahraa shehab Ahmed | 23 |
| 330 - 324 | The effect of biological control agents in controlling the larval stages of <i>Spodoptera littoralis</i> in Basra Governorate Zahraa J. Khadim and Ali Zachi Abdulqader | 24 |



ISSN (Print) 1994-697X

ISSN (Online) 2706-722X

DOI:

<https://doi.org/10.5463/3/2333-023-052-006>

Myofunctional Appliance for Class III

Malocclusion: A review

Maryam S. Al-Yasari¹, Layth M. Kareem², Ihab N. Safi³, Mustafa S. Tukmachi⁴, Zahra S. Naji⁵

^{1,3,4} Department of prosthodontics, College of Dentistry, University of Baghdad, Iraq.

² Department of orthodontics, College of Dentistry, University of Baghdad, Iraq.

⁵ Gulf Medical University, Ajman, UAE.

¹ Maryam.S.561@codental.uobaghdad.edu.iq

¹ <https://orcid.org/0009-0008-4280-5938>

Abstract:

Early management of Class III malocclusion poses many challenges for orthodontic specialists, as the cause of this malocclusion can be multifactorial, being either skeletal, dental, or both skeletal and dental. The aim of this comprehensive review was to shed light on up-to-date orthopedic appliances that can be used in the growth modification of Class III malocclusion along with other treatment modalities that can be used in growing patients for early correction of skeletal/dental components of class III malocclusion. Furthermore, a review of bone-anchored appliances and their combined use with the orthopedic appliances is also discussed in this study.

Keywords: Myofunctional appliance. Angle class III malocclusion. Interceptive treatment. Skeletal anchorage. Mixed dentition.

Introduction

The treatment of skeletal class III malocclusion is considered one of the most pretentious challenges in orthodontics (Fabozzi et al., 2021) (Kadhom et al., 2024). The etiological factors for Class III malocclusions comprise many issues of skeletal and dental constituents. In such cases, the condition might be recognized by many features, such as (Azamian & Shirban, 2016) (Ganesh et al., 2020), (Rédua, 2020):

- Mandibular prognathism, in which there is a protrusion of the lower jaw.
- Maxillary retrognathism, in which there is a retrusion of the upper jaw.
- Retrusive maxillary dentition.
- Protrusive mandibular dentition.
- A combination of the above.

Practically, class III conditions can be found as pseudo Class III in which a premature interference effects the muscular reflex during mandibular closure or as factual Class III cases (Paoloni et al., 2021). With ageing, class III malocclusion becomes more complicated (Valgadde & Chougule, 2016). Therefore, timely orthodontic involvement could help in

preventing serious irreparable soft and hard tissue deviations that may appear in advanced stages (Sarangal et al., 2020).

The concept of myofunctional appliances utilizes forces generated by the orofacial muscles to alter the way of maturation in those patients who are still in the phase of growth (Kumar et al., 2021). Although they're best known for treatment of class II malocclusions, this does not prohibit their use for class III malocclusions in developing dentition (Fleming & Lee, 2016).

This article presents an up-to-date review concerning myofunctional and orthopedic appliances, demonstrating their diverse types, modes of action, and times of intervention, in addition to the other new concepts of treatment that have been proposed in the early management of the dental and skeletal constituents of class III malocclusion.

Type of Appliances

According to the site of anchorage, appliances are classified into two categories: intra-oral appliances and extra-oral appliances (Azamian & Shirban, 2016). These categories may overlap during the course of treatment and will be discussed at the end of this section.

1. Intra-Oral Appliances

The intra-oral appliances include the following:

1.1 Reverse Twin Block (RTB)

This appliance is a modification of the traditional twin-block used for class II malocclusion (Yavan et al., 2022). In this appliance, the blocks are essentially reversed so that the lower block (coating the lower molars) closes off distal to the upper block (coating the upper premolars), as shown in Figure 1 (Albajalan et al., 2020). The upper device can integrate a midline screw, which is turned twice a week for arch harmonization if needed (Fleming & Lee, 2016). The mode of action is primarily dentoalveolar, causing the upper anterior teeth to procline and the lower anteriors to retrocline, and skeletal changes are minimal (Yavan et al., 2022). The best time for treatment with this device is the initial mixed dentition period (6–9 years). It can be fixed to the teeth and be worn all day (24 hours), which hastens the treatment time. This means it can be worn during normal functions of the day (speaking and eating) (Novalia, 2018).

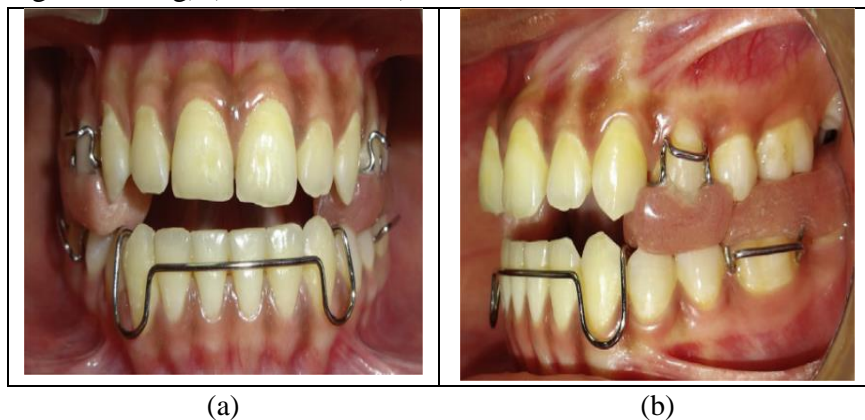


Figure 1: Reverse Twin Block appliance. (a) Frontal view; (b) Lateral view (Singh et al., 2018).

1.2 Fränkel Functional Regulator 3 (FR3)

It's the most frequently used functional appliance for class III correction. It is a soft tissue-borne device planned to dislodge soft tissues and muscles that limit maxillary growth, as shown in Figure 2 (Fleming & Lee, 2016). The effects are skeletal alongside dentoalveolar changes (Di Luzio et al., 2017). The lower portion of the device constrains mandibular development (Ji et al., 2020). The FR-3 can be utilized during the primary, mixed, and early permanent dentition phases. It is worn for around 20 hours per day, being removed only while eating and playing contact sports (Graber et al., 2016).

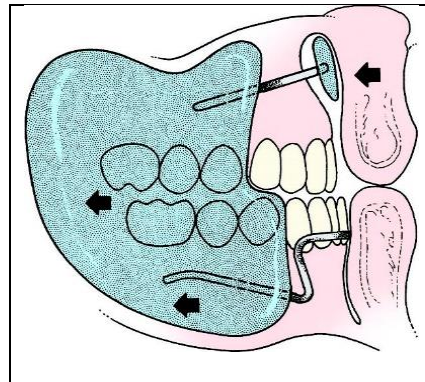


Figure 2: Fränkel Functional Regulator (FR3). The buccal and labial vestibular shields are designed to protect the maxillary alveolus from the forces of the adjacent soft tissues (Graber et al., 2016).

1.3 Reverse Bionator (III)

As Balters suggests in his hypothesis, Class III patients tend to occlude with the tongue positioned more anteriorly than normal (Garattini et al., 1998). The reverse bionator is therefore designed to keep the tongue in a more posterior and higher position (Yang et al., 2022), as shown in Figure 3. The effects are mainly dentoalveolar and, it's mostly used in the mixed dentition period in patients with pseudo-class III malocclusions with the upper anterior teeth tipped palatally, causing forward mandibular movement on closure from postural rest to habitual occlusion (Abeas, 2024). It's recommended to be worn for at least 22 hours a day (Azamian & Shirban, 2016).




Figure 3: Reverse Bionator III. (a) Frontal view; (b) Lateral view (<https://dvddental.it/ortodonzia.html>).

1.4 Eschler Appliance or Progenic Appliance

This appliance has a reformed labial arc made to touch the labial surface of lower incisors, with an occlusal bite-raising appliance made of acrylic (Novais Machado et al., 2020), as shown in Figure 4. This will help in normal growth of the maxilla, besides the adjustment of the reversed overjet (Almeida et al., 2011). The effect of Eschler appliance is mainly dentoalveolar with slight skeletal effect. The device is applied in cases with pseudo-class III occlusion exhibiting forward displacement of the mandible. It's suggested to be worn for at least 14 hours per day and, the best treatment time is mixed and permanent dentition, from 9 to 12 years of age (Novais Machado et al., 2020) (Sarangal et al., 2020).

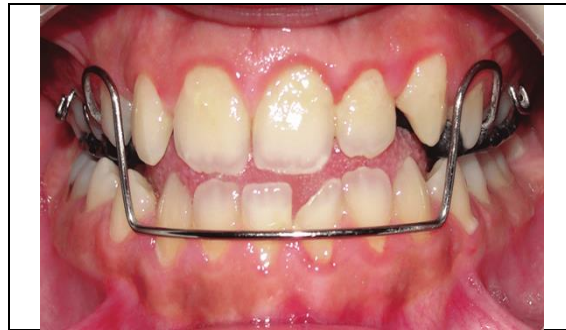

Figure 4: Eschler appliance (Majanni & Hajeer, 2016).

1.5 Modified Tandem Appliance (MTA)

This appliance was specifically constructed to get over complaint problems patients had with the traditional facemasks (Valgadde & Chougule, 2016). Chun et al. (Chun et al., 1999) defined MTA as a convenient and more appealing device than traditional appliances due to the fact that it's removable and used intraorally, as shown in Figure 5. The effects are combined skeletal and dental. The mode of action is anterior advancement of the maxilla accompanied by posterior rotation of the lower jaw (Yavan et al., 2022) (Valgadde & Chougule, 2016). The device is recommended to be worn for about 14-16 hours per day (Valgadde & Chougule, 2016).

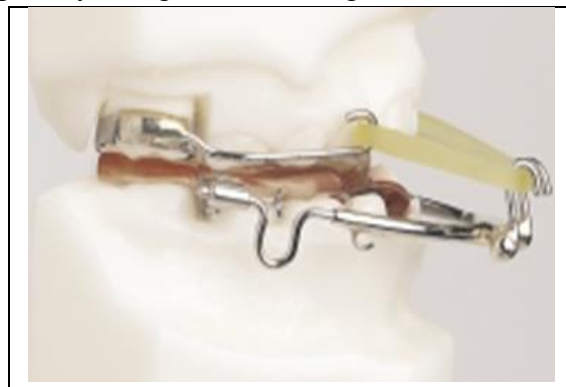


Figure 5: Modified traction bow (Valgadde & Chougule, 2016).

1.6 Double Plate Appliance (DPA)

The appliance is fabricated as angulated acrylic blocks with Class III elastics that are positioned among the upper molars and lower canines, as shown in Figure 6 (Azamian & Shirban, 2016) (Gencer et al., 2015). The double plate device is usually used in conjunction with a facemask. The

effects are mainly dental and it's shown to be effective in patients with maxillary deficiency (Kaygısız et al., 2018). The average age is around 10 years, and patients are expected to wear it daytime and night apart from for meals (Üçem et al., 2004).

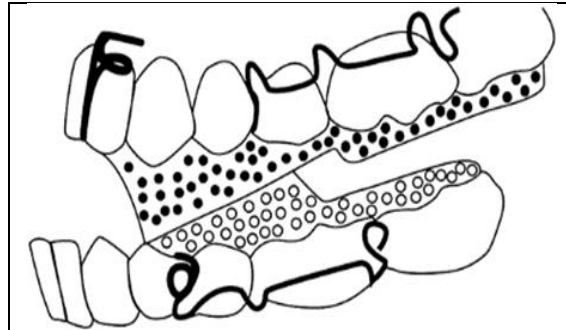


Figure 6: Schematic illustration of the double plate appliance (Azamian & Shirban, 2016).

1.7 Carrier Motion 3D Class III Appliance (CM3)

This is a new appliance with a very simple and uncomplicated design. It has gained wide acceptance among clinical specialists for the past decade (McNamara Jr et al., 2021) (Gentile et al., 2023). It simply consists of bilateral bars joined to the buccal surface of the lower posterior teeth (from the first premolar to the first permanent molar) and a solitary tube-like orthodontic bracket joined to the upper first or second permanent molar by means of intraoral elastics (Kamel & Taha, 2023) (An et al., 2020), as shown in Figure 7. According to a study performed by Shroff (Shroff, 2021), it has been concluded that most of the treatment effects produced by the CM3 were dentoalveolar in origin, with slight skeletal changes. It can be used in the management of class III malocclusion in growing and non-growing patients as a substitute for surgery. Class III elastics are worn full-time, except during meals (Carrière, 2016).

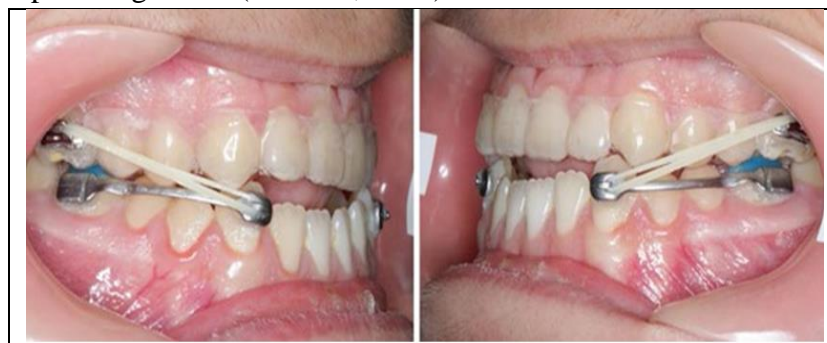

Figure 7: Carrier Motion 3D class III Appliance (Shroff, 2021).

1.8 Pushing Splint 3 (PS3)

The appliance is made up of three parts: two acrylic splints and one Forsus L-pin module for each side, as shown in Figure 8 (Galeotti et al., 2021). The positive features of the PS3 allow the delivery of forces used to improve maxillary jaw relationship in the sagittal plane. In addition to vertical vectors that are capable of restricting the vertical growth of alveolar and skeletal constituents (on the contrary to the facemask, which boosts the vertical growth) (Martina et al., 2020) (Galeotti et al., 2024). Therefore, this appliance is best suited in the treatment of Class III hyper-divergent patients. The effects are combined skeletal and dental, and patients are instructed to wear the appliance for a minimum of 14 hours per day (Martina et al., 2019).

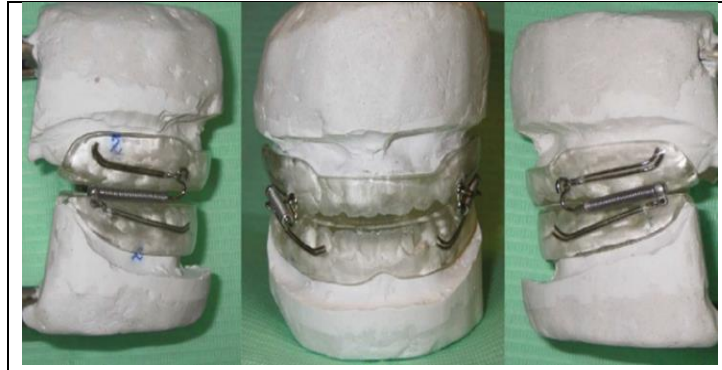

Figure 8: The PS3 appliance (Martina et al., 2019).

2. Extra-oral Appliances

The extra-oral appliances are classified into the following:

2.1 Chin-cup Therapy

Skeletal class III malocclusion having an almost regular maxilla and a reasonably protruded mandible can be managed with chin-cup therapy; with the cup being attached to the chin and an elastic strap covering the head (Ko et al., 2004) (Gür & Erdem, 2023), as shown in Figure 9. The evidence suggests that reducing mandibular prognathism is more effective when treatment is started in the primary or early mixed dentition (varying from one year of age to as far as 4 years) (Ngan & Moon, 2015). The main goal of such an early treatment is to inhibit or redirect mandibular growth posteriorly (Ngan & Moon, 2015) (Martina et al., 2020). Patients are trained to wear the appliance for 14 hours per day (Mousoulea et al., 2016).

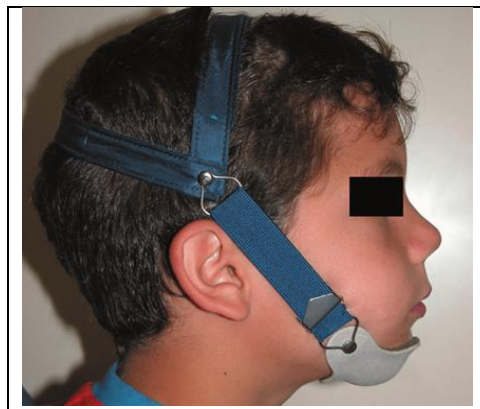

Figure 9: Chin-cup Appliance (Torres et al., 2012).

2.2 Facemask (Reverse-pull headgear, Protraction headgear)

Facemasks are considered one of the main tools used to intervene in emerging skeletal class III malocclusion, as shown in Figure 10. According to Zhou et al. (Zhou et al., 2024) the ideal treatment time is the initial mixed dentition period parallel with the emerging of the upper permanent incisors, that's prior to 9 years of age. Nevertheless, Kapust et al. (Kapust et al., 1998) stated that protraction therapy can also be effective in elder youngsters aged 10–14 years, but to a slighter degree. A facemask being anchored to the forehead and chin is indicated for patients with slight to moderate skeletal class III malocclusion due to maxillary retrognathism (Liu et al., 2021). In addition, it can be

utilized for stabilization after maxillary osteotomy (Zere et al., 2018). A facemask should be used for 12–14 hours per day (Yepes et al., 2014).

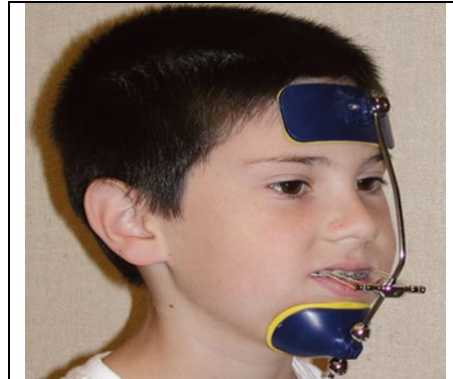

Figure 10: Protraction facemask (Littlewood, 2019).

2.3 Protraction Alone Vs Protraction with Rapid Maxillary Expansion

One of the debatable subjects is the use of rapid maxillary expansion (RME) in conjunction with facemask therapy. Usually class III skeletal patients tend to have a restricted maxilla in the horizontal aspect alongside the anteroposterior aspect; therefore, this expansion might be a useful tool for the treatment (Seppala & Cobourne, 2017) (Lee et al., 2021). This attitude has been further developed by formulating a system identified as Alt-RAMEC (Alternating Rapid Maxillary Expansion and Contraction). The Alt-RAMEC system labels the use of alternating weeks of rapid maxillary expansion and constriction to achieve disarticulation of the maxilla. This disarticulation will enhance maxillary forward advancement (Liu et al., 2015) (de Souza et al., 2019) (Lee et al., 2021). “Hyrax expander” is one of the most commonly used expansion apparatuses (Nienkemper et al., 2013). the “Hybrid hyrax” involves two mini-screws planted in the anterior palate, which increases the skeletal anchorage, as shown in Figure 11 (Hourfar et al., 2016). Hybrid hyrax-facemask combined therapy has become a popular treatment strategy for management of class III malocclusion in growing patients (Feldmann & Bazargani, 2017).

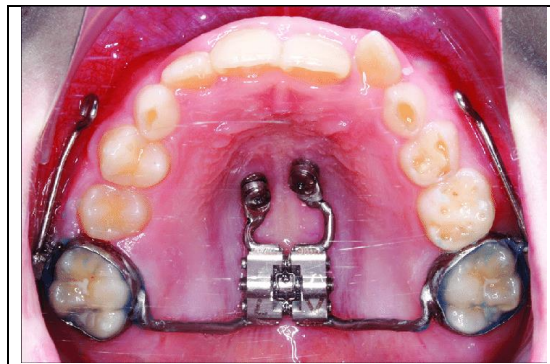


Figure 11: Hybrid hyrax expander involving two mini-screws with buccal hooks for attachment of the facemask (Wilmes, 2022).

Bone Anchored Appliances

Due to the drawbacks reported with tooth-borne appliances (i.e., facemasks, RME), which include mesial tipping and extrusion of maxillary dentition and lingual tipping of lower incisors in addition to posterior rotation of the mandible, bone-anchored maxillary protraction (BAMP) appliances have

been introduced (Zere et al., 2018) (Cha et al., 2021) (Tarraf et al., 2023). The bone-anchored methodology typically involves two approaches: facemask traction to skeletal anchorage and class III elastics to maxillary and mandibular miniplates.

Facemask Traction to Skeletal Anchorage

Obviously, one of the main drawbacks of individual treatment with facemasks is the unfavorable tooth movement that deteriorates from the skeletal change (Seiryu et al., 2020) (Zhou et al., 2024). Temporary implants are now offered as mini titanium screws that provide skeletal anchorage aimed at maxillary advancement, as shown in Figure 12. In order to be effective, it's better that these mini-screws be applied as bilateral mini-implants on the anterior maxilla (Karthi et al., 2013) (Seiryu et al., 2020). It has been confirmed with three adequate arbitrary practical studies that superior skeletal advancement can be obtained when facemasks are anchored to skeletal instead of dental constituents, achieving around 4-5 mm of protraction near the border (Yepes et al., 2014) (Sharifi & Alhuwaizi, 2023). However, this approach poses a negative aspect in such a way that bone maturity in young patients is not sufficient and implant placement surgery is quite invasive, implicating that orthopedic traction with mini-screws should not be started before 10 years of age (De Clerck et al., 2009).

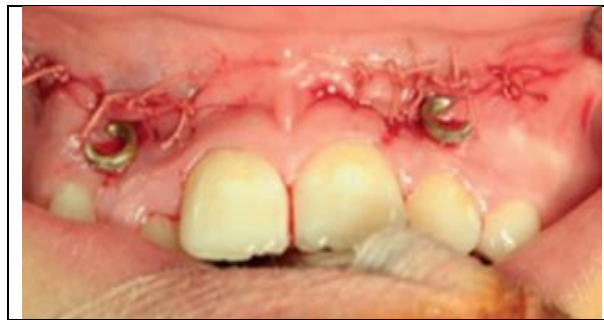

Figure 12: Skeletal anchorage for attachment of a facemask for maxillary protraction (Proffit et al., 2018).

Class III Elastics to Maxillary and Mandibular Miniplates

This method was first presented by De Clerck et al. (De Clerck et al., 2010) in which bilateral miniplates are inserted on the upper jaw at the area of zygomatic buttresses and on the lower jaw at the symphyseal region, as shown in Figure 13. With this methodology, the extraoral facemask is no longer necessary, and intermaxillary traction will be applied 24 hours a day so that the forces directed to the jaws will be light (Esenlik et al., 2015). In optimal treatment by this method, inter-maxillary class III elastics are retained for almost 12 months, which is considered sufficient time to manage jaw discrepancy. Followed then by a second stage of treatment with a fixed orthodontic device (Fakharian et al., 2019) (Yilmaz et al., 2015).

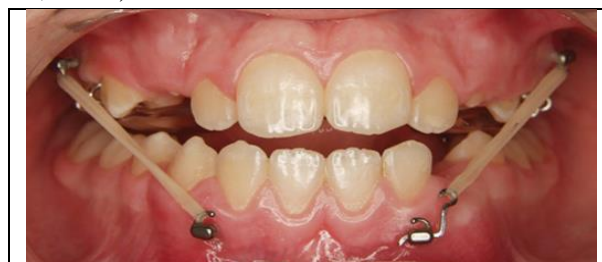

Figure 13: Class III Elastics to Maxillary and Mandibular Miniplates (Proffit et al., 2018).

Discussion

Management of class III malocclusion in developing patients is still considered a puzzling part of the advanced orthodontic field. Numerous treatment strategies have been evolved in the literature using extraoral and intraoral appliances for orthopedic and orthodontic management of class III cases. For example, in cases with maxillary skeletal retrusion frankel functional regulator is the appliance of choice. On the other hand, the orthopedic chin-cup therapy is mainly recommended in cases characterized by mandibular prognathism. The extraoral facemask is widely used in the United States for Class III malocclusion with retruded maxillary arch. (Graber et al., 2016). As for the time of intervention, it is very well acknowledged that skeletal class III malocclusion is initiated early in life and it does not resolve by itself; instead, it may worsen with time if timely intervention is not initiated. Hence, early management has been recommended, such as in the deciduous dentition period or pre-pubertal growth phase (Lee et al., 2021).

However, formulating an appropriate treatment plan and choosing a specific appliance over another is greatly reliant on precise diagnosis and judicious clinical evaluation of the condition, which embraces the following (Proffit et al., 2018) (Fakharian et al., 2019): evaluating the patient's age, phase of growth, assessing the patient's compliance, determining the cause of the malocclusion, and the severity of the skeletal problem. All of the mentioned above should be combined with the radiographical examinations (i.e., cephalometric analysis) in order to formulate the most appropriate treatment plan.

Turpin established a table presenting positive and negative aspects that service judgement making on developing class III malocclusions which are listed in Table 1 (Ngan, 2002) (Zere et al., 2018). Turpin proposed that timely intervention is directed for patients who offered positive features, while those who offered negative features should postpone their treatment until growth is completed. Another suggestion made by the author is concerned with warning the patients of the possibility that a surgery may be required, even after an effective interceptive treatment (Ngan et al., 2014).

Table 1: Turban's positive and negative factors

| Positive Factors | Negative Factors |
|-----------------------------------|-----------------------------|
| Convex facial form | Concave facial form |
| Anteroposterior functional shift | No anteroposterior shift |
| Equal growth of condyle | Unequal growth of condyle |
| Growing patient | Adult patient |
| Minor skeletal discrepancy | Severe skeletal discrepancy |
| Patient compliance anticipated | Poor compliance anticipated |
| No genetic mandibular prognathism | Genetic pattern recognized |
| Decent facial esthetics | Reduced facial esthetics |

Conclusion

This paper attempts to provide a comprehensive review of the orthopedic treatment approach for class III malocclusion which embraces a variety of appliances and their novel adaptations that have demonstrated their value and efficiency in the timely treatment of developing class III patients. We reported different strategies and the skills of the combined use of dual appliances. Nevertheless, the choice of selecting a particular appliance over another is greatly reliant on the origin of the disharmony and the great analysis of each situation by the orthodontist.

All appliances labelled in this paper would be beneficial when practitioners applied them in judgmental and precise ways.

References

- Abeas, Kasem Ahmed. 2024. Mesioclusion: A Review of Treatment Approaches. Hilla University College Journal For Medical Science 2.1-9.
- Albajalan, Osama Bahaa, Nawres Oraibi Alazzawi, Nor Ashikeen Mukti & AR Samsudin. 2020. Effectiveness of Treatment with Reverse Twin-Block and Reverse Pull Face Mask on Dental Arches of Class III Malocclusion: A Randomized Clinical Trial. Journal of International Dental and Medical Research 13.708-13.
- Almeida, Marcio Rodrigues de, Renato Rodrigues de Almeida, Paula Vanessa Pedron Oltramari-Navarro, Ana Cláudia de Castro Ferreira Conti, Ricardo de Lima Navarro & José Gustavo Dala Déa Camacho. 2011. Early treatment of Class III malocclusion: 10-year clinical follow-up. Journal of Applied Oral Science 19.431-39.
- An, So-Youn, So-Young Park, Eun-Young Jeon & Youn-Soo Shim. 2020. Application of New Appliances for Management of Growing Class III Malocclusion Child: Comparazation Case Reports. Journal of Dental Hygiene Science 20.118-24.
- Azamian, Zeinab & Farinaz Shirban. 2016. Treatment options for class III malocclusion in growing patients with emphasis on maxillary protraction. Scientifica 2016.8105163.
- Carrière, Luis. 2016. Nonsurgical Correction of Severe Skeletal Class III Malocclusion. Journal of clinical orthodontics: JCO 50.216-30.
- Cha, Bong-Kuen, Jae Hyun Park, Dong-Soon Choi & Insan Jang. 2021. Facemask therapy with skeletal anchorage: A possible alternative to orthognathic surgery. Orthodontics & Craniofacial Research 24.13-20.
- Chun, Youn-Sic, Seong-Gweon Jeong, Joon Row & Sung-Jae Yang. 1999. A new appliance for orthopedic correction of Class III malocclusion. Journal of clinical orthodontics: JCO 33.705-11.
- De Clerck, Hugo, Lucia Cevidanes & Tiziano Baccetti. 2010. Dentofacial effects of bone-anchored maxillary protraction: a controlled study of consecutively treated Class III patients. American journal of orthodontics and dentofacial orthopedics 138.577-81.
- De Clerck, Hugo J, Marie A Cornelis, Lucia H Cevidanes, Gavin C Heymann & Camilla JF Tulloch. 2009. Orthopedic traction of the maxilla with miniplates: a new perspective for treatment of midface deficiency. Journal of Oral and Maxillofacial Surgery 67.2123-29.
- de Souza, Ricardo Alves, José Rino Neto & João Batista de Paiva. 2019. Maxillary protraction with rapid maxillary expansion and facemask versus skeletal anchorage with mini-implants in class III patients: a non-randomized clinical trial. Progress in orthodontics 20.1-11.

- Di Luzio, Cecilia, Amelia Bellisario, Martina Caputo, Maria Luisa Favale & Francesca Squillace. 2017. The use of Frankel-3 in Class III Malocclusion: Short term and Long term effects.
- Esenlik, Elçin, Cahide Ağlarıcı, Gayem Eroğlu Albayrak & Yavuz Fındık. 2015. Maxillary protraction using skeletal anchorage and intermaxillary elastics in Skeletal Class III patients. The Korean Journal of Orthodontics 45.95-101.
- Fabozzi, Filomena Federica, Ludovica Nucci, Antonia Correr, Fabrizia d'Apuzzo, Lorenzo Franchi & Letizia Perillo. 2021. Comparison of two protocols for early treatment of dentoskeletal Class III malocclusion: Modified SEC III versus RME/FM. Orthodontics & Craniofacial Research 24.344-50.
- Fakharian, Mehrnaz, Erfan Bardideh & Mostafa Abtahi. 2019. Skeletal Class III malocclusion treatment using mandibular and maxillary skeletal anchorage and intermaxillary elastics: a case report. Dental press journal of orthodontics 24.52-59.
- Feldmann, Ingalill & Farhan Bazargani. 2017. Pain and discomfort during the first week of rapid maxillary expansion (RME) using two different RME appliances: a randomized controlled trial. The Angle Orthodontist 87.391-96.
- Fleming, Padhraig S & Robert T Lee. 2016. Orthodontic functional appliances: theory and practice: John Wiley & Sons.
- Galeotti, Angela, Stefano Martina, Valeria Viarani, Lorenzo Franchi, Roberto Rongo, Vincenzo D'Antò & Paola Festa. 2021. Cephalometric effects of Pushing Splints 3 compared with rapid maxillary expansion and facemask therapy in Class III malocclusion children: a randomized controlled trial. European Journal of Orthodontics 43.274-82.
- Galeotti, Angela, Valeria Viarani, Lorenzo Franchi, Stefano Martina, Roberto Rongo, Vincenzo D'Antò, Roberto Uomo, Francesco Aristei & Paola Festa. 2024. Cephalometric changes of pushing splints 3 compared to rapid maxillary expansion and facemask therapy on the airway space in class III growing patients: A randomized clinical trial. Orthodontics & Craniofacial Research.
- Ganesh, Gayatri, Tulika Tripathi & Priyank Rai. 2020. Orthopaedic and orthodontic treatment with hyrax, Class III elastics on mandibular miniplates, maxillary mini-implants in a Class III adolescent: A case report. International Orthodontics 18.827-38.
- Garattini, Giovanna, Luca Levrini, Paolo Crozzoli & Aurelio Levrini. 1998. Skeletal and dental modifications produced by the Bionator III appliance. American journal of orthodontics and dentofacial orthopedics 114.40-44.
- Gencer, Deniz, Emine Kaygisiz, Sema Yüksel & Tuba Tortop. 2015. Comparison of double-plate appliance/facemask combination and facemask therapy in treating Class III malocclusions. The Angle Orthodontist 85.278-83.
- Gentile, Alberto, Donatella Ferrara, Marta Maci & Domenico Ciavarella. 2023. Correction of Class III Malocclusion Treated with Carriere® Motion™. Case Reports in Dentistry 2023.8848581.
- Graber, Lee W, Robert L Vanarsdall, KW Vig & Greg J Huang. 2016. Orthodontics-e-book: current principles and techniques. St. Louis, MO: Elsevier.
- Gür, Gözde & Dilek Erdem. 2023. Early Treatment of a Class III Patient with Chincup: A Case Report. Cumhuriyet Dental Journal 26.105-11.

- Hourfar, Jan, Gero Kinzinger, Björn Ludwig, Julia Spindler & Jörg Lisson. 2016. Differential treatment effects of two anchorage systems for rapid maxillary expansion: a retrospective cephalometric study. *Journal of Orofacial Orthopedics/Fortschritte der Kieferorthopädie* 77.
- Ji, Li-Li, Dan-Xu Sun, Ling-Bo Shi, Hee-Moon Kyung, Li Bing & Xiu-Ping Wu. 2020. Cambios Morfológicos del Regulador funcional Frankel III en dentición mixta con maloclusión clase III. *International Journal of Morphology* 38.1053-59.
- Kadhom, Zainab Mousa, Alaa Faleh Albo Hassan & Shaymaa Shaker Taha. 2024. Ethics In Orthodontic Clinical Practice:(A review article). (Humanities, social and applied sciences) *Misan Journal of Academic Studies* 23.148-54.
- Kamel, Hiba A & Shaym Sh Taha. 2023. Frictional Resistance in Orthodontics-A Review. (Humanities, social and applied sciences) *Misan Journal of Academic Studies* 22.253-63.
- Kapust, Andrew J, Peter M Sinclair & Patrick K Turley. 1998. Cephalometric effects of face mask/expansion therapy in Class III children: a comparison of three age groups. *American journal of orthodontics and dentofacial orthopedics* 113.204-12.
- Karthi, Muthukumar, Gobichettipalayam Jagatheeswaran Anbuselvan & Bhandari Pawan Kumar. 2013. Early correction of class III malocclusion with rapid maxillary expansion and face mask therapy. *Journal of Pharmacy and Bioallied Sciences* 5.S169-S72.
- Kaygısız, Emine, Erdal Bozkaya, Tuba Tortop, Dervis Emre Ercan & Sema Yuksel. 2018. Long term results of double plate appliance and facemask combination in the treatment of Class III malocclusion: cephalometric analysis. *Acta Odontologica Turcica* 35.62-68.
- Ko, Young-II, Seung-Hak Baek, James Mah & Won-Sik Yang. 2004. Determinants of successful chincup therapy in skeletal class III malocclusion. *American journal of orthodontics and dentofacial orthopedics* 126.33-41.
- Kumar, Saurav, Nadira Hassan, Ravi Anjan, Himanshu Kaushik & Sana Shaikh. 2021. MYOFUNCTIONAL APPLIANCES: Book Rivers.
- Lee, Wei-Cheng, Yi-Shing Shieh, Yu-Fang Liao, Cho-Hao Lee & Chiung Shing Huang. 2021. Long-term maxillary three dimensional changes following maxillary protraction with or without expansion: a systematic review and meta-analysis. *Journal of Dental Sciences* 16.168-77.
- Littlewood, SJ. 2019. *An introduction to orthodontics: Oxford university press.*
- Liu, Weitao, Yanheng Zhou, Xuedong Wang, Dawei Liu & Shaonan Zhou. 2015. Effect of maxillary protraction with alternating rapid palatal expansion and constriction vs expansion alone in maxillary retrusive patients: a single-center, randomized controlled trial. *American journal of orthodontics and dentofacial orthopedics* 148.641-51.
- Liu, Yuyao, Renya Hou, Hairu Jin, Xin Zhang, Zuping Wu, Zixuan Li & Jie Guo. 2021. Relative effectiveness of facemask therapy with alternate maxillary expansion and constriction in the early treatment of Class III malocclusion. *American journal of orthodontics and dentofacial orthopedics* 159.321-32.
- Majanni, Abdulmalek Mr & Mohammad Y Hajeer. 2016. The Removable Mandibular Retractor vs the Bone-anchored Intermaxillary Traction in the Correction of skeletal class III Malocclusion in children: A Randomized Controlled Trial. *The Journal of Contemporary Dental Practice* 17.361-71.
- Martina, Roberto, Vincenzo D'Antò, Vittoria De Simone, Angela Galeotti, Roberto Rongo & Lorenzo Franchi. 2020. Cephalometric outcomes of a new orthopaedic appliance for Class III malocclusion treatment. *European Journal of Orthodontics* 42.187-92.

- Martina, Stefano, Roberto Martina, Lorenzo Franchi, Vincenzo D'Antò & Rosa Valletta. 2019. A new appliance for Class III treatment in growing patients: pushing splints 3. *Case Reports in Dentistry* 2019.9597024.
- McNamara Jr, James A, Lorenzo Franchi, Laurie McNamara McClatchey, Sarah E Kowalski & Camaron C Cheeseman. 2021. Evaluation of adolescent and adult patients treated with the Carriere Motion Class III appliance followed by fixed appliances. *The Angle Orthodontist* 91.149-56.
- Mousoulea, Sophia, Ioannis Tsolakis, Efstratios Ferdianakis & Apostolos I Tsolakis. 2016. The effect of chin-cup therapy in class III malocclusion: a systematic review. *The open dentistry journal* 10.664.
- Ngan, Peter. 2002. Biomechanics of maxillary expansion and protraction in Class III patients. *American journal of orthodontics and dentofacial orthopedics* 121.582-83.
- Ngan, Peter, Hong He & Benedict Wilmes. 2014. *Treatment in Class III malocclusions in the growing patients: Bentham Science Publishers Ltd Sharjah.*
- Ngan, Peter & Won Moon. 2015. Evolution of Class III treatment in orthodontics. *American journal of orthodontics and dentofacial orthopedics* 148.22-36.
- Nienkemper, Manuel, Benedict Wilmes, Alexander Pauls & Dieter Drescher. 2013. Maxillary protraction using a hybrid hyrax-facemask combination. *Progress in orthodontics* 14.1-8.
- Novais Machado, KDO, DD Oliveira & AW Machado. 2020. Early treatment of anterior crossbite with eschler appliance: Two case reports. *J Dent Probl Solut* 7.063-67.
- Novalia, Trio. 2018. *Treatment of Class III Malocclusion with Reverse Twin Block in the Growing Child (Case Report). Paper presented to the International Dental Conference of Sumatera Utara 2017 (IDCSU 2017), 2018.*
- Paoloni, V, FC De Razza, L Franchi & P Cozza. 2021. Stability prediction of early orthopedic treatment in Class III malocclusion: morphologic discriminant analysis. *Progress in orthodontics* 22.1-10.
- Proffit, William R, Henry Fields, Brent Larson & David M Sarver. 2018. *Contemporary Orthodontics-E-Book: Contemporary Orthodontics-E-Book: Elsevier Health Sciences.*
- Rédua, Renato Barcellos. 2020. Different approaches to the treatment of skeletal Class II malocclusion during growth: Bionator versus extraoral appliance. *Dental press journal of orthodontics* 25.69-85.
- Sarangal, Heena, Ritu Namdev, Swati Garg, Natasha Saini & Parul Singhal. 2020. Treatment modalities for early management of Class III skeletal malocclusion: a case series. *Contemporary clinical dentistry* 11.91-96.
- Seiryu, Masahiro, Hiroto Ida, Atsushi Mayama, Satoshi Sasaki, Shutaro Sasaki, Toru Deguchi & Teruko Takano-Yamamoto. 2020. A comparative assessment of orthodontic treatment outcomes of mild skeletal Class III malocclusion between facemask and facemask in combination with a miniscrew for anchorage in growing patients: a single-center, prospective randomized controlled trial. *The Angle Orthodontist* 90.3-12.
- Seppala, Maisa & Martyn T Cobourne. 2017. *Development of the Dentition. Orthodontic Management of the Developing Dentition: An Evidence-Based Guide.1-19.*
- Sharifi, Haidar M AL & Akram F Alhuwaizi. 2023. Fluoride and Titanium Based Orthodontic Arch wire. (Humanities, social and applied sciences) *Misan Journal of Academic Studies* 22.198-205.

- Shroff, Bhavna. 2021. Controversial Topics in Orthodontics: Can We Reach Consensus?
- Singh, Harpreet, Pranav Kapoor, Poonam Sharma, Raj Kumar Maurya & Tanmay Mittal. 2018. Skeletal Class III correction in permanent dentition using reverse twin block appliance and fixed mechanotherapy. *The Saudi Dental Journal* 30.379-88.
- Tarraf, Nour Eldin, Oyku Dalci, Kerem Dalci, Ayse Tuba Altug & M Ali Darendeliler. 2023. A retrospective comparison of two protocols for correction of skeletal Class III malocclusion in prepubertal children: hybrid hyrax expander with mandibular miniplates and rapid maxillary expansion with face mask. *Progress in orthodontics* 24.3.
- Torres, Fernando César, Renato Rodrigues de Almeida, Renata Rodrigues de Almeida-Pedrin, Fernando Pedrin & Luiz Renato Paranhos. 2012. Dentoalveolar comparative study between removable and fixed cribs, associated to chincup, in anterior open bite treatment. *Journal of Applied Oral Science* 20.531-37.
- Üçem, Tuba Tortop, Neslihan Üçüncü & Sema Yüksel. 2004. Comparison of double-plate appliance and facemask therapy in treating Class III malocclusions. *American journal of orthodontics and dentofacial orthopedics* 126.672-79.
- Valgadde, Sneha & Kishor Chougule. 2016. Early treatment of Class III malocclusion with a tandem traction bow appliance. *APOS Trends in Orthodontics* 6.228-28.
- Wilmes, Benedict. 2022. Appliance First” or “Bone First” for miniscrew assisted rapid palatal expansion. *APOS Trends in Orthodontics* 12.3-6.
- Yang, Xue, Guangyun Lai & Jun Wang. 2022. Effect of orofacial myofunctional therapy along with preformed appliances on patients with mixed dentition and lip incompetence. *BMC Oral Health* 22.586.
- Yavan, Mehmet Ali, Gülcan Çetin Taşkiran, Gökçenur Gökçe & Nihal Hamamcı. 2022. Therapeutic Effects of Removable Intraoral Class III Appliances on Dentofacial Structures: A Comprehensive Literature Review. *Süleyman Demirel Üniversitesi Sağlık Bilimleri Dergisi* 13.153-60.
- Yepes, Eliana, Paula Quintero, Zulma Vanessa Rueda & Andrea Pedroza. 2014. Optimal force for maxillary protraction facemask therapy in the early treatment of class III malocclusion. *European Journal of Orthodontics* 36.586-94.
- Yilmaz, Hanife Nuray, Hasan Garip, Tulin Satilmis & Nazan Kucukkeles. 2015. Corticotomy-assisted maxillary protraction with skeletal anchorage and Class III elastics. *The Angle Orthodontist* 85.48-57.
- Zere, Edlira, Prabhat Kumar Chaudhari, Jitendra Sharan, Kunaal Dhingra & Nitesh Tiwari. 2018. Developing Class III malocclusions: challenges and solutions. *Clinical, cosmetic and investigational dentistry*.99-116.
- Zhou, Nan, Zhengxian Zhu, Liting Jiang, Xuechao Wang & Niansong Ye. 2024. Long-term effects of protraction facemask combined with fixed appliance therapy in severe skeletal Class III adolescent: A case report with 5-year follow-up. *International Journal of Surgery Case Reports*.110306.